



Automatically Extract the Left and Right Ventricular Myocardium from CT Images by Using Region Based Segmentation

Jackulin DuraiRani.A¹, Yamini.C², Sivaranjani.B³, Rekha.A⁴, Jothi.S⁵

PG Scholar, Dept., of CSE, Dr.N.G.P. Institute of Technology, Tamil Nadu, India^{1,3,4,5}

Assistant Professor, Dept., of CSE, Dr.N.G.P. Institute of Technology, Tamil Nadu, India²

ABSTRACT: Seeded Region Growing is the more gorgeous method in medical image segmentation by using high level information of images for selecting seeds for segmentation. This SRG algorithm that provides the most efficient for fixing the labels for pixels and also for segmentation. This paper represents the automatic system for segmenting the left and right ventricular myocardium CT images by using Region growing method. This algorithm follows the focus on fixing the labels for region growing segmentation. This algorithm that gives the most accurate segmentation of Myocardium from CT images the delineation of the myocardial wall which is a exacting task due to large differences in myocardial shapes and quality of an image. In this paper, we describe an automatic method for extracting the myocardium from the left and right ventricles from CT images. In the method, the left and right ventricles are detected, by first identifying the endocardium and epicardium and then segmenting the myocardium. After that, a seed region-growing method is applied to extract the epicardium of the ventricles. In particular, the location of the endocardium of the left ventricle is determined via using an active contour model on the blood-pool surface. To localize the right ventricle, the active contour model is applied on a heart surface extracted based on the left ventricle segmentation result, which gives the high accuracy.

KEYWORDS: Seeded Growing Method, Left and Right ventricles, Apex point, Myocardium wall segmentation

I. INTRODUCTION

Mobile Seeded region growing approach to image segmentation is used to segment an image into regions with respect to a seeds which can be determined by manually or by automatically. The set of seeds, S_1, S_2, \dots, S_q , in each step of SRG involves one additional pixel to one of the seed sets. Moreover, these source seeds are further replaced by the cancroids' of these generated homogeneous regions, R_1, R_2, \dots, R_n , by adding additional pixels in step by step manner. The pixels in the unique region are flagged by the same sign and the pixels in different regions are labeled by different sign. All these flagged pixels are called the allocated pixels, and the distinct pixels are called the unallocated pixels.

II. RELATED WORK

Model-based strategies became dominant during this analysis to urge associate correct and strong segmentation. Normally, a heart surface is formed by learning the geometric or intensity options of the guts from internal organ pictures. whereas in segmentation, a usually used framework is 1st globally orienting the model to a picture then deforming this model to suit image content. International localization is achieved by detection the geometric or intensity of the images. Deformations are performed by optimizing associate objective operate outlined between the model parameters and images. Above all, the model-based methods are often approximately classified supported whether or not these models are applied explicitly or implicitly for segmentation. Within the first variety of strategies, generally a heart surface model is fitted to images for segmentation. In ASM model a applied math form model referred to as the purpose Distribution Model is learned from a collection of aligned shapes mistreatment the principal element analysis (PCA) technique, that is then iteratively aligned to image boundaries. Active look models (AAMs) extend this idea by incorporating grey level data and were utilized in segmenting the left and right ventricles from adult male pictures. The segmentation within the constant quantity models like ASMs and AAMs are restricted to the form



International Journal of Innovative Research in Computer and Communication Engineering

(An ISO 3297: 2007 Certified Organization)

Vol. 3, Issue 4, April 2015

area wherever the guts models are embedded. In these strategies, associate annotated heart surface model is unshapely to match image content by optimizing affine or similarity transformations outlined between the model parameters and image options. Above all, landmark points on the interventricular septum were wont to guide the segmentation in. Rather than segmenting a pre-aligned model, atlas-based strategies use form data implicitly by directly registering atlas image to a target image. However, the segmentation of the cardiac muscle wall of the self-propelled vehicle has been neglected in these progressive model-based strategies. Model-free strategies also are wide wont to explore the characteristics of heart pure mathematics or intensity distribution from alternative views. For instance, the random forests methodology was wont to model the geometric and intensity options within the cardiac muscle region for delineating the cardiac muscle. For a varying literature review of heart segmentation methods, the way to localize the model may be a less studied topic, particularly for these strategies mistreatment deformable models, that tend to urge stuck in undesirable native extreme once started while not a decent data formatting. Typically, the geometric options of the guts are used for localization, within the 55 serous membrane was initialized by checking out a circular structure in an exceedingly blood pool mask obtained via thresholding. The empirical rule was used in distinctive the ventricle cavity. Samples of additional advanced localization strategies embody the generalized remodel and improvement of similarity transformation for a heart model. Atlas-based registration has additionally been used for coarse data formatting.

One observation that will be utilized for the localization is that the ventricles are salient parts on the guts surface. Wherever the form decomposition/segmentation technique can be utilized to cluster the surface into purposeful parts supported some given criteria as in special effects and geometric modeling. For instance, a surface is also hierarchically rotten into regions of deep concavities by mistreatment fuzzy agglomeration and graph partition techniques. Applications of form segmentation in medical imaging are often found in heart modeling from pictures and cardiovascular disease neck detection on vessel surfaces.

Active contour models have additionally been applied on surfaces to refine coarse segmentations or extract objects of interest. Form segmentation technique would be a strong tool for ventricle localization as a result of ventricles is distinguished parts on the guts surface. Among the few applications of this method in internal organ image segmentation, the narrowing of vessels round the atrium cordias was detected by merging native options supported given criteria to extract the atrium cordias.

In this paper, we have a tendency to propose a technique for mechanically extracting the cardiac muscle wall from internal organ CT pictures, which integrates region growing with form segmentation in an exceedingly natural manner. During this framework, the form segmentation provides seed regions for region growing whereas the latter reconstructs a heart surface for shape segmentation. Specifically, the segmentation method starts by localizing the 55 serous membrane. In contrast to the localization strategies delineated thus far, our methodology relies on the observation that the 55 may be a salient element on the blood pool surface, which might be known on the surface by utilizing form segmentation techniques. Once the 55 is decided, the self-propelled vehicle is localized supported the segmentation of the 55. The self-propelled vehicle serosa is initialized within the same manner as in localizing the 55 serosa. Finally, these cardiac muscle surfaces are segmented by using SRG algorithm mistreatment the initial segmentations as a constraint.

The following steps to be followed to segment the LV and RV:

1. We present an automatic segmentation method for both ventricles with high accuracy and performance.
2. The proposed method is able to segment thin-layer structures like the myocardium of the RV, which has been omitted by some of these latest methods.
3. The overall system is complete automatic system in that SRG algorithm is involved are booted automatically and robustly, other than in these systems where active contours are either used to segment the left ventricle. In addition, no training image is required in our method.

International Journal of Innovative Research in Computer and Communication Engineering

(An ISO 3297: 2007 Certified Organization)

Vol. 3, Issue 4, April 2015

III. METHOD OVERVIEW

This paper represents complete automatic system for segmenting the left and right ventricle myocardium form CT images without using the trained images. The following flow chart [20] that represents the complete system to segment the myocardium from left and right ventricles.

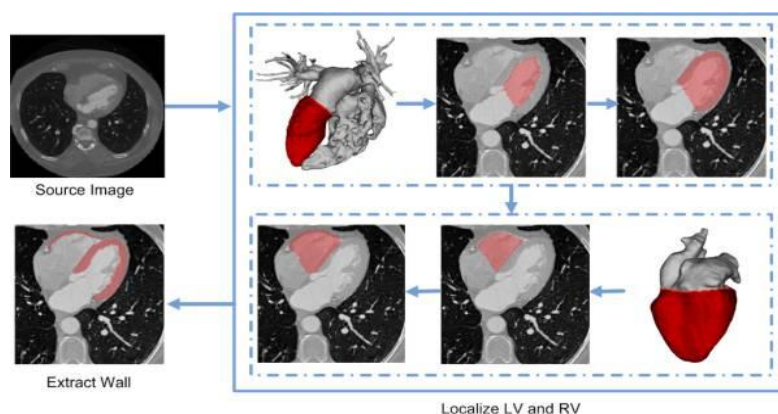


Fig.1. Flow Chart

Before beginning the automation system step, the heart surface is calculable by the blood surface. Then, detect the apex purpose of the ventricle by victimisation the relative physical coordinate of the system in CT pictures. The heart ventricle is automatically detected by examining the distribution of the extent sets starting from the apex purpose that is further refined by activity the geometric active contour model on the blood pool surface. This region growing algorithm decomposes the surface into a pair of parts, and also the one contains the apex purpose is chosen as a result of the initial serosa surface. Once the endocardial surface is found, its corresponding mask is obtained via pasteurization. Then, a variational region-growing methodology is utilized to extract the initial epicardial surface supported the saros segmentation. Finally, these 2 surfaces area unit refined by employing a vigorous contour model with a kind constraint, and additionally the guts muscle is obtained by extracting voxels between these surfaces.

The following steps that can be involved in automatic segmentation of myocardium:

1. Left and right ventricle localization and myocardial wall segmentation
2. Endocardium Segmentation
3. Epicardium Segmentation
4. Myocardium wall segmentation

A. Localization of the Left Ventricle:

Let orientation of a CT image is given and there is enough contrast to the blood pool and myocardium. The localization of the Left Ventricle is done by searching for a boundary on the blood pool surface as follows:

- Extract Blood Pool Surface

Since CT pictures have mark grey levels, the supply image is threshold to spotlight the blood pool region. Then, a morphological gap operator is applied to get rid of clangorous arteries and cut spines that will be residing within the same connected part of the center. The most important connected part is chosen and triangulated because the blood pool surface.



International Journal of Innovative Research in Computer and Communication Engineering

(An ISO 3297: 2007 Certified Organization)

Vol. 3, Issue 4, April 2015

- Detect Apex Point

Let the reference frame of the supply image is Left-Posterior-Inferior (LPI). The anatomy of the pig heart is sort of similar to human with a distinct long-axis orientation. The long axis of the human heart is informed towards the anterior plane whereas the pig is inclined within the inferior direction. Then, a region of is explored so it is massive enough to hide the apex point. After that, the foremost anterior and inferior points at intervals the neighborhood $N(p_{lv})$ are designated because the human and pig apex points, severally.

- Find an Initial Cut Contour

Initial cut contours determined by $C0_{lv}$, by analyzing the distance field sourcing from the apex point, the lengths of contours on the distance field increased regularly, and then drop slowly. After a particular point, they are growing gradually followed by sharp reductions..The total length of an is contour d may be calculated as

$$h(d, \tilde{d}) = \{c_0 + c_1 d + c_2 d^2 a e^{-(d-\mu)^2 / 2\sigma^2} \text{if } d \leq \tilde{d} \text{ if } d > \tilde{d}, \dots \dots \dots (1)$$

$$j^* = \text{argmin}_j (\text{argmin}_{c_0, c_1, c_2} \sum_{i=1}^j (h(d_i, d_j) - l_i)^2 + \text{argmin}_{\mu, \sigma} \sum_{i=j+1}^n (\log(h(d_i, d_j)) - \log(l_i))^2) \dots \dots \dots (2)$$

- Extract the LV Endocardium

The endocardial surface M_{lvendo} is closed by triangulating the points on the cut contour one hundred fifty-five, that is Rasterized to urge a mask image Γ_{lvendo} . To get rid of noise and appendage muscles, the morphological closing

operator is applied within the hogged hull of the endocardial surface.

- Segment the LV Epicardium

One way of initializing the serosa mask is by dilating the serous membrane to a given distance. The weather of Γ_{lvpei} is also determined by selecting voxels at intervals an exact distance vary to the Γ_{lvendo} boundary. This works well for a cardiac muscle wall with an almost uniform thickness. Here, otherwise is projected to initialize Γ_{lvpei} by utilizing a variation region-growing methodology that's driven by the strong statistics of image intensities. just like dilation-based ways, a distance field from Γ_{lvendo} is computed and a tiny low strip region lying between d_{in} and d_{out} is chosen because the seed region for the serosa mask. Typically, the values area unit set to $d_{in} = \text{two millimeter}$ and $d_{out} = \text{four millimeter}$. The blood pool voxels area unit excluded from this region. Once the seed region is set, the robust-statistics-based energy useful is then outlined as

$$ERS(\phi) = \lambda RS \int_{\Omega} -p(\mathbf{f}(x)) H(\phi(x)) dx + (1 - \lambda RS) \int_{\Omega} \delta(x) |\nabla \phi(x)| dx, \quad (3)$$

B. Localization of the Right Ventricle:

The following strategy is used to localize the RV:

- Reconstruct the Heart Surface

The intensity within the self-propelled vehicle blood pool might not be as homogenous because the cardinal. To spot the self-propelled vehicle, a heart surface is initially reconstructed by taking the cardinal serous membrane as a seed



International Journal of Innovative Research in Computer and Communication Engineering

(An ISO 3297: 2007 Certified Organization)

Vol. 3, Issue 4, April 2015

region to begin the variation region-growing method. In implementation, the parameter λ_{RS} was set as $\lambda_{RS} = 0.9$ in order that the intensity force term plays a number one role whereas competitive with the smoothing force to explore the complete heart region. The surface is portrayed as a triangulated surface, denoted by M_{ht} . Since the blood pool occupies the bulk of the cardinal endocardial mask, the growing method shows the next tendency to expand brighter regions than the darker ones. Combining the impact of the smoothing term, the growing method bit by bit captures a heart region.

- Find an Initial Cut Contour

The close point from M_{ht} to the Left Ventricle apex p_{apx} is used to start the reconstructing the distance field on M_{ht} . Then, the distance field is sampled at a regular interval of 1.5mm. Let $\{p_i\}$, $i = 1 \dots m$, the points in contour C . The distance between the contour and the cut contour C_{lv} of M_{bp} is calculated by

$$d(C, C_{lv}) = \frac{1}{m} \sum_{i=1}^m |N_{lv} \cdot (p_i - p_c)|, \dots \dots \dots (4)$$

- Segment the RV Endocardium

The initial cut contour C_{0vs} is calculated by using the geometric SRG algorithm. The surface determined by C_{vs} includes both the LV and RV, which is rasterized to get a mask for the ventricles, denoted by \tilde{I}_{vs} . The RV endocardium mask is obtained by removing the LV and blood pool voxels from \tilde{I}_{vs} .

C. Extract the Myocardial Wall:

To extract the heart muscle wall, the mask pictures of the ventricles are refined by using a lively contour technique with a form constraint that permits native variations round the segmental masks. After that, the outlier voxels are excluded to urge a whole wall structure.

- Extract the Myocardial Wall

The cardiac muscle wall is outlined because the volume between the serosa and visceral pericardium masks. The bulk of the wall is determined by playacting the logic XOR operation between the serosa and visceral pericardium masks of the 55 and recreational vehicle, severally. Note that the contour evolution method returns closed surfaces.

IV. CONCLUSION AND FUTURE WORK

We have concluded an automatic system for segmenting the left and right ventricles from cardiac CT images using SRG algorithm. This method automatically segments the LV and RV by SRG algorithm with region-growing techniques. Particularly, each ventricle is determined by identifying the endocardium of left and right ventricles and then segmenting the epicardium by SRG algorithm. Segmented left ventricle is used to segment the Right Ventricle. The differences of the heart are managed by using the features obtained on-line. Its performance has been determined by calculating the errors between automatic and manual segmentations. In this test, the SRG achieves high accuracy and robustness. In future work, we planned to apply the automatic system to clinical applications

REFERENCES

1. Liangjia Zhu, Yi Gao, Vikram Appia, Anthony Yezzi, Chesnal Arepalli, Tracy Faber, Arthur Stillman, and Allen Tannenbaum, Fellow, IEEE "A Complete System for Automatic Extraction of Left Ventricular Myocardium From CT Images Using Shape Segmentation and Contour Evolution"
2. C. Petitjean and J. N. Dacher, "A review of segmentation methods in short axis cardiac MR images," Med. Image Anal., vol. 15, no. 2, pp. 169–184, 2011.
3. T. F. Cootes, C. J. Taylor, D. H. Cooper, and J. Graham, "Active shape models-their training and application," Comput. Vis. Image Understand., vol. 61, no. 1, pp. 38–59, 1995.



International Journal of Innovative Research in Computer and Communication Engineering

(An ISO 3297: 2007 Certified Organization)

Vol. 3, Issue 4, April 2015

4. H. C. van Assen, M. G. Danilouchkine, M. S. Dirksen, J. H. Reiber, and B. P. Lelieveldt, "A 3-D active shape model driven by fuzzy inference: Application to cardiac CT and MR," *IEEE Trans. Inf. Technol. Biomed.*, vol. 12, no. 5, pp. 595–605, Sep. 2008.
5. H. C. van Assen, M. G. Danilouchkine, F. F. Frangi, S. Ordas, J. J. Westenberg, J. H. Reiber, et al., "SPASM: A 3D-ASM for segmentation of sparse and arbitrarily oriented cardiac MRI data," *Med. Image Anal.*, vol. 10, no. 2, pp. 286–303, 2006.
6. T. F. Cootes, G. J. Edwards, and C. J. Taylor, "Active appearance models," *IEEE Trans. Pattern Anal. Mach. Intell.*, vol. 23, no. 6, pp. 681–685, Jun. 2001.
7. S. C. Mitchell, B. Lelieveldt, R. J. van der Geest, J. G. Bosch, J. H. C. Reiber, and M. Sonka, "Multistage hybrid active appearance model matching: Segmentation of left and right ventricles in cardiac MR images," *IEEE Trans. Med. Imag.*, vol. 20, no. 5, pp. 415–423, May 2001.
8. S. Essafi, G. Lings, and N. Paragios, "Hierarchical 3D diffusion wavelet shape priors," in *Proc. Int. Conf. Comput. Vis.*, 2009, pp. 1717–1724.
9. O. Ecabert, J. Peters, H. Schramm, C. Lorenz, J. von Berg, and M. Walker, "Automatic model-based segmentation of the heart in CT images," *IEEE Trans. Med. Imag.*, vol. 27, no. 9, pp. 1189–1201, Sep. 2008.
10. X. Zhuang, K. S. Rhode, R. S. Razavi, D. J. Hawkes, and S. Ourselin, "A registration-based propagation framework for automatic whole heart segmentation of cardiac MRI," *IEEE Trans. Med. Imag.*, vol. 29, no. 9, pp. 1612–1625, Sep. 2010.
11. V. S. Lempitsky, M. Verhoek, J. A. Noble, and A. Blake, "Random forest classification for automatic delineation of myocardium in realtime 3D echocardiography," in *Proc. 5th Int. Conf. Funct. Imag. Model. Heart*, 2009, pp. 447–456.
12. S. Kichenassamy, A. Kumar, P. Olver, A. Tannenbaum, and A. Yezzi, "Gradient flows and geometric active contour models," in *Proc. 5th Int. Conf. Comput. Vis.*, Washington, DC, USA, 1995, pp. 810–815.
13. V. Caselles, R. Kimmel, and G. Sapiro, "Geodesic active contours," *Int. J. Comput. Vis.*, vol. 22, no. 1, pp. 61–79, 1997. [17] T. F. Chan and L. A. Vese, "Active contours without edges," *IEEE Trans. Image Process.*, vol. 10, no. 2, pp. 2029–2039, Feb. 2001.
14. X. Wang, D. S. Huang, and H. Xu, "An efficient local Chan-Vese model for image segmentation," *Pattern Recognit.*, vol. 43, no. 3, pp. 603–618, 2010.
15. L. Chen, Y. Zhou, Y. Wang, and J. Yang, "Rapid and brief communication: GACV: Geodesic-aided C-V method," *Pattern Recognit.*, vol. 39, no. 7, pp. 1391–1395, Jul. 2006.
16. S. Lankton, D. Nain, A. Yezzi, and A. Tannenbaum, "Hybrid geodesic region-based curve evolutions for image segmentation," *Proc. SPIE*, vol. 6510, p. 65104U, Mar. 2007.
17. S. Lankton and A. Tannenbaum, "Localizing region-based active contours," *IEEE Trans. Image Process.*, vol. 17, no. 11, pp. 2029–2039, Nov. 2008.
18. A. Tsai, A. Yezzi, W. Wells, C. Tempany, D. Tucker, A. Fan, et al., "A shape-based approach to the segmentation of medical imagery using level sets," *IEEE Trans. Med. Imag.*, vol. 22, no. 2, pp. 137–154, Feb. 2003.
19. V. Appia, B. Ganapathy, A. Abufadel, A. Yezzi, and T. Faber, "A regions of confidence based approach to enhance segmentation with shape priors," *Proc SPIE.*, vol. 7533, p. 753302, May 2010.
20. V. Appia, B. Ganapathy, A. Yezzi, and T. Faber, "Localized principal component analysis based curve evolution: A divide and conquer approach," in *Proc. IEEE Int. Comput. Vis. Conf.*, Nov. 2011, pp. 1981–1986.