

Congenital Anestrus in Cattle—a Report of 3 Cases

H K Bhattacharyya*, M R Fazili, B A Buchoo

Teaching Veterinary Clinical Complex, Faculty of Veterinary Sciences and Animal Husbandry, SKUAST-K, Shuhama-Alusteng, Srinagar–190006, J&K, India

Case Report

Received date: 03/07/2015

Accepted date: 29/11/2015

Published date: 02/12/2015

*For Correspondence

H K Bhattacharyya, Teaching Veterinary Clinical Complex, Faculty of Veterinary Sciences and Animal Husbandry, SKUAST-K, Shuhama-Alusteng, Srinagar–190006, J&K, India, Tel: 91-9435564391.

E-mail: drhiranyabh@yahoo.co.in

Keywords: Congenital anestrus, Heifer, Crossbred cow

ABSTRACT

Occurrence of 3 different rare conditions of congenital anestrus namely bilateral ovarian hypoplasia, bilateral ovarian agenesis and freemartin in 3 different heifers is reported. These three conditions were recorded out of more than 6000 clinical examinations in heifers made during last 14 years by the authors.

INTRODUCTION

Congenital anestrus refers to anestrus arises from the congenital defects of reproductive tract. Depending on the severity of the condition the affected animal may be infertile or sterile^[1,2]. The present communication reports three different conditions of congenital anestrus in crossbred cow.

CASE HISTORY, OBSERVATION AND DIAGNOSIS

Animal No1: A crossbred Jersey heifer, aged 4 years, weighing approx. 200 kg was presented with the history of anestrus. The heifer was treated with vitamin cum mineral supplement for last one year by a veterinarian and finally with hormone GnRH by another local veterinarian with no success and referred to the referral clinic. The animal looked like steer with long leg, narrow pelvis and underdeveloped udder with small teats. Clinico-gynaecological examination revealed pea sized, smooth ovaries. Cervix was of normal size but uterus was very small. The case was diagnosed as bilateral ovarian hypoplasia (BOH).

Animal No2: A black colored Jersey heifer was presented with the history of anestrus. The heifer was treated for delayed puberty by para-veterinarian in the field with several drugs including hormonal therapy with no success for which it was referred to our team. Critical Per-rectal examination revealed absence of both ovaries with small uterine horns (~ 2 cm length). Cervix could not be palpated. Examination by vaginal speculum of 6" length revealed short vaginal canal. The case was diagnosed as bilateral ovarian agenesis (BOA).

Animal No3: A 21 months old crossbred Holstein Friesian heifer presented with the history of not showing estrus since its birth. As per history the heifer was born co-twin to a bull. Detailed gynecological examination revealed enlarged clitoris and failure in identifying cervix, uterus and ovaries. The animal was bullish type with presence of tuft of hairs at ventral commissure of vulva. A test tube was inserted into the vagina but could not be inserted beyond 10 cm into the vagina. The case was diagnosed as freemartin (**Figures 1 and 2**).



Figure 1. Freemartin heifer showing bullish characteristics.

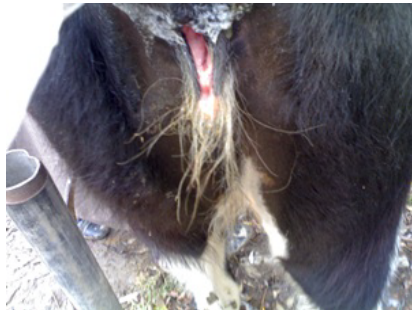


Figure 2. Freemartin heifer with enlarged clitoris and tuft of hair in ventral commissure of vulva.

DISCUSSION

Ovarian hypoplasia is a condition, where one or both ovaries are smaller than normal. It is caused by single recessive gene with incomplete penetration [1]. Affected ovary is characterized by lack of primordial follicles [3]. The condition may be unilateral or bilateral and/or partial or complete. Bilateral complete hypoplastic females are anoestrous and are sterile while partial hypoplastic females exhibit estrus and conceive and may produce normal calves transmitting undesirable characteristics to the next generation [4].

Bilateral ovarian agenesis is extremely rare condition [2], caused by inherited autosomal dominant gene [5]. Roberts [1] reported gonadless heifer which appeared normal until breeding age, but no estrus occurred with underdeveloped udder. Genital tracts of these heifers are also juvenile and underdeveloped.

Freemartins have a short vagina that ends blindly without communication with uterus. It can be differentiated from normal heifer on the basis of length of vagina and on presence or absence of cervix [2]. 'Test tube test' checks the vaginal depth [2,6,7]. In adult normal animal a test tube (blunt end) can be inserted upto 30 cm in the vagina; whereas in adult abnormal heifer tube only goes about 8-10 cm in the vagina. In calves of 1-4 weeks of age, the vagina is normally 13-15 cm in length compared to 5-6 cm in abnormal heifers. Diagnosis at this stage can be made using a blunt probe which should be inserted initially at an angle of 45° from the ventral floor for 5 cm and then angled at about 10-15° below to avoid impinging on the hymen [8]. About 92% freemartins are sterile [9]. In cattle with multiple fetuses, the chorionic placental blood vessels form a common circulation between the fetuses prior to sexual differentiation, allowing anti-mullerian duct hormone and testosterone secreted by the male foetus to inhibit development of female reproductive tract and freemartin results [7].

All these defects are congenital, out of which ovarian hypoplasia and ovarian agenesis were hereditary defects. Since all the animals were sterile, the owners of these animals were advised to cull the animals from the herd to reduce the cost of production. The owners of all these three animals contacted us when they slaughtered these animals (for meat) as per our advice given earlier for confirmatory diagnosis. Following slaughter of the animals, the whole genitalia were collected and brought to the laboratory for gross/histopathological examination. The ovaries of the hypoplastic females (Animal No 1) were sent to Department of Pathology for confirmation and reported about complete lack of primordial follicles in the infantine ovary. Infantine genital system with no gonads was observed in animal no 2. In animal no 3 cervix, vagina, uterus, oviduct and ovaries were found underdeveloped.

The three conditions described in the present study are very rare condition [1,2] under Indian situation. The conditions were recorded first time among more than 6000 virgin heifers (live cows) examined (clinico-gynaecological examination) during last 14 years by the authors and is very difficult to compare with the results of different authors; since, most of the references found in the available literature are based on the postmortem findings only.

The incidence of ovarian hypoplasia in Indian cattle has been reported between 0.08 to 4.3% [10,11], although in exotic cattle high incidence (10-23%) is reported [12]. In India as high as 9.7% hypoplastic cases were recorded among 889 cows over a period of 6 years [13]. The reports of ovarian agenesis from India are very meager [4]. The incidence of freemartinism in Indian cattle and buffaloes has been reported very low ranging from 0.10 to 0.20% [14,15]. Kumi-Diaka et al. [16] recorded hypoplasia in 13 (0.43%) and freemartinism in 2 (0.07%) out of 3000 post mortem cases of slaughtered cows in Nigeria.

REFERENCES

1. Roberts SJ (1998) In: Veterinary Obstetrics and Genital Diseases. (2ndedn), CBS Publication and Distributors (Indian reprint), India.
2. Noakes ED, et al. (2001) In: Arthur's Veterinary Reproduction and Obstetrics. (8thedn), Harcourt (India) Private Ltd., New Delhi.
3. Settergen I. Ovarian hypoplasia in heifers due to germ cell weakness. *Theriogenology*. (1997);47:531-539.
4. Kumar PR, et al. Anestrus in cattle and buffaloes: Indian perspective. *Adv Anim Vet Sci*. (2014);2:124-138.
5. Gilmore LA. (1952) In: Dairy Cattle Breeding. F.B.Lippincott Co., NYC.
6. Eilts BE. (2007) Disturbances of bovine estrous cycle: Anestrus. School of Veterinary Medicine, Louisiana State University.
7. Anonymous. (2008) Reproductive system: Congenital and Inherited Anomalies of the Reproductive System. In: Merck Veterinary Manual. Merck and Co. Inc., Whitehouse, NJ, USA.
8. Long S E. Development and diagnosis of freemartinism in cattle. *In Pract*. (1990);12:208-210.
9. McFeely RA, et al. Chromosome studies in 14 cases of Intersex in domestic mammals. *Cytogenetics*. (1967);6:242-253.
10. Rao AVN. and Murthy AK. Studies on reproductive disorders in cows in Andhra Pradesh. *Indian Vet J*. (1972);53:156.
11. Kumar S and Agarwal SK. Studies on ovarian dysfunction in rural bovines. *Indian Vet Med J*. (1986);10:11-12.
12. Lagerlof N and Boyd H. Ovarian hypoplasia and other abnormal condition in sexual organs of cattle of Swedish highland breed: Result of postmortem examination of over 6000 cows. *Cornell Vet*. (1953);43:52.
13. Hussain PM and Muniraja L. Study in the incidence of reproductive disorders of bovines in a part of southern Karnataka. *Livestock Adviser*. (1984);9:13-16.
14. Rao AVN and Murthy ST. Incidence of freemartinism in the Indian water buffaloes. *Indian Vet J*. (1980);57:783.
15. Sharma U, et al. Freemartinism in a cross bred heifer. *Intas Polivet*. (2004);5:164-165.
16. Kumi-Diaka J, et al. Significance of atrophic ovaries in livestock production in northern Nigeria. *Vet Rec*. (1981);108:277-278.