

# Research & Reviews: Journal of Dental Sciences

## Management of Two Palatal Canals in Maxillary First Molar- a Case Report

Pradeep gade<sup>1\*</sup>, Hanuman sudhakar<sup>2</sup>, Navata gade<sup>3</sup>

<sup>1</sup>Senior Lecturer, Department Of Conservative Dentistry & Endodontics, Gitam Dental College And Hospital, Andhra Pradesh, India

<sup>2</sup>DDS, Adjunct faculty, JSS dental college and hospital.Mysore.

<sup>3</sup>MDS, Root canal dental clinic, Visakhapatnam

### Case Report

Received date: 23/10/2015

Accepted date: 04/12/2015

Published date: 13/12/2015

#### \*For Correspondence

DFlat no:216, M.V.V.Presidency, Old Venkojipalem, Visakhapatnam-530022, Andhra Pradesh, Tel: 9963056600, India.

E-mail: pradeepgade1@gmail.com

Keywords: Two palatal canals, Anatomical variations, Root canal

#### ABSTRACT

Endodontic success is based on proper access cavity, proper cleaning and shaping, and root canal obturation. Knowledge of both normal and abnormal anatomy of the tooth determines outcome of the endodontic therapy. The purpose of this study is to present a clinical case of a maxillary first molar with two palatal canals, one mesio-buccal and one disto-buccal canal. This case report aids to remind clinicians that such anatomical deviations should be taken into consideration during endodontic treatment of the maxillary molars.

### INTRODUCTION

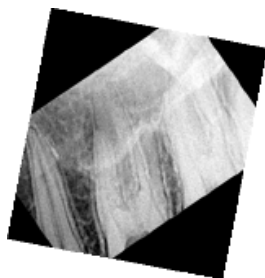
A successful outcome for root canal treatment relies on adequate removal of micro-organisms from the canal system and prevention of recolonisation or propagation of residual micro-organisms through the placement of a root filling that obturates the space entirely, combined with a restoration that produces a satisfactory coronal seal <sup>[1]</sup>. Variations in dental anatomy are found in all groups of teeth, and knowledge of these variations, particularly in relation to the location and treatment of all canals, is the key to successful endodontic therapy, since the ability to find and properly treat all root canals may prevent future failures <sup>[2]</sup>. Baratto-Filho et al. assessed internal morphology of maxillary first molars by 3 different methods. They found that second palatal canal prevalence in *ex vivo* assessment, 2.05%, in clinical assessment, 0.65%, and by cone-beam computed tomography, 4.55% <sup>[3]</sup>.

On the basis of the above mentioned literature, this paper reports an example of a maxillary first molar with an unusual anatomy (two palatal canals) and describes the importance and difficulties of the endodontic treatment.

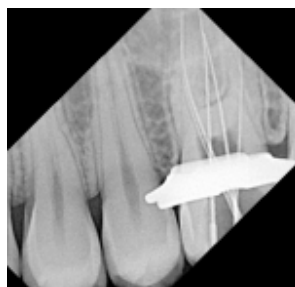### CASE REPORT

A 42-year-old female patient presented with signs of irreversible pulpitis. She complained of pain on the left side of the face for several days prior to her appointment. The patient's medical history was noncontributory. After extensive clinical and radiographic examination (**Figure 1**), the maxillary left first molar was prepared for nonsurgical endodontic therapy. The patient received local anesthesia of 2% lidocaine with 1:80000 epinephrine. After removing caries of the tooth, a conventional endodontic access opening was made. Rubber dam was placed. Clinical examination with a DG-16 endodontic explorer (Hu-Friedy, Chicago, IL, USA) revealed 4 distinct orifices: two palatals with one large buccal orifice and one distal orifices. The conventional triangular access was modified to a trapezoidal shape to improve access to the palatal canals. The root canals were negotiated and the working length was determined using apex locator (Root ZX). The working length radiograph was taken using bisecting angle technique (**Figure 2**). The root canals were cleaned and biomechanical preparation was performed using the crown-down technique with Protaper Universal Rotary NiTi files

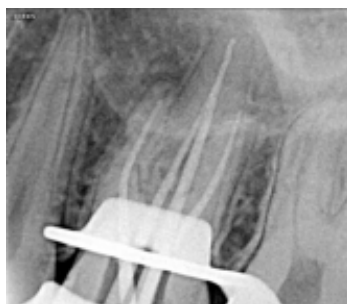(Dentsply, Maillefer, Switzerland) along with GLYDE (Dentsply Maillefer Company, USA). The root canals were copiously irrigated with 3% sodium hypochlorite. The canals were obturated using guttapercha points (**Figure 3**) & AH plus root canal sealer using single cone technique. Post-obturation radiograph revealing 4 different canals was taken (**Figures 4 and 5**).



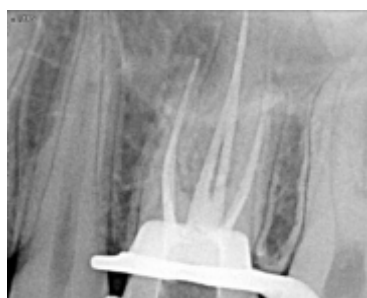**Figure 1.** Preoperative Radiograph.



**Figure 2.** Working Length Radiograph.



**Figure 3.** Mastercone Radiograph.



**Figure 4.** Immediate Obturation Radiograph.

## DISCUSSION

For effective endodontic therapy, dentists should dedicate equal care to all steps of the endodontic treatment. However, one of the chief concerns of endodontists is the cleaning, shaping and disinfection of the root canal. The most frequent cause of endodontic failure is the apical percolation and subsequent diffusion stasis into the canal. The main reasons for this failure are incomplete canal obturation or an untreated canal<sup>[4]</sup>. According to Cohen and Burns<sup>[5]</sup>, canals are often not treated because they are not located. Despite Krasner and Rankow<sup>[6]</sup> having defined the laws of orifice location of the root canals, drawing conclusions that the orifices of the root canals are always located at the junction of the walls and the floor, at the angles in the floor-wall junction and at the terminus of the root developmental fusion. The present case report describes a new variant with four separate canals, mesiobuccal root, two individual palatal mesiopalatal and distopalatal with its own separate canal, and distobuccal root with a single canal. Despite such common suggestions about access, it is most important that careful attention is paid to any evidence of additional canals.

Christie et al.<sup>[7]</sup> speculated that maxillary molars with two palatal roots may be encountered once every 3 years in a busy endodontic practice.

## **CONCLUSION**

Though the frequency of a second palatal canal is not high, it is significant to take this variation into consideration during root canal therapy of maxillary molars in order to ensure long term treatment success.

## **REFERENCES**

1. Briggs PF, Scott BJ. Evidence-based dentistry: endodontic failure—how should it be managed. *Br Dent J.* 1997;183:159-164.
2. Cobankara FK, Terlemez A, Orucoglu H. Maxillary first molar with an unusual morphology: report of a rare case. *Oral Surg Oral Med Oral Pathol Oral Radiol Endod* 2008;106:62-65.
3. Baratto Filho F, Zaitter S, Haragushiku GA, De Campos EA, Abuabara A, et al. “Analysis of the internal anatomy of maxillary first molars by using different methods,” *Journal of Endodontics.* 2009;35:337-342.
4. European Society of Endodontology (2006) Quality guidelines for endodontic treatment: consensus report of the European Society of Endodontology. *Int Endod J.* 2006;39: 921-930.
5. Cohen S, Burns RC. *Pathways of the pulp.* 7th edition. Missouri: Mosby. 1998.
6. Krasner P, Rankow HJ. Anatomy of the pulp-chamber floor. *J Endod.* 2004;30: 5-16.
7. Christie WH, Peikoff MD, Fogel HM. Maxillary molars with two palatal roots: a retrospective clinical study. *J Endod.* 1991;17: 80-84.