

Research & Reviews: Journal of Dental Sciences

Proximity of the Maxillary First Molar Roots and the Maxillary Sinus Floor Using Cone Beam Computed Tomography

Shereen M Shokry^{1,2}, Eman E. El Wakeel^{2,3*}, Tasnim AL Sbaih⁴, May Al Otaibi⁵, Malak AL Osaimi⁵

¹Department of Oral Radiology, Cairo University, Cairo, Egypt

²Assistant Professor Riyadh Colleges of Dentistry and Pharmacy, Riyadh, Saudi Arabia

³Department of Anatomy and Embryology, Benha University, Egypt

⁴Demonstrator, Oral & Maxillofacial Surgery Department, Riyadh Colleges of Dentistry and Pharmacy, Saudi Arabia

⁵Riyadh Colleges of Dentistry and Pharmacy, Saudi Arabia

Research Article

Received date: 06/04/2016

Accepted date: 07/05/2016

Published date: 16/05/2016

*For Correspondence

Dr. Eman E. El Wakeel, M.B.B.Ch, M.Sc, Ph.D, Assistant professor of Anatomy Riyadh Colleges of Dentistry and Pharmacy, P.O. Box 84891 – Riyadh 11681, Kingdom Saudi Arabia Girls Block

E-mail: eman.elwakeel@riyadh.edu.sa

Keywords: Maxillary first molar, Maxillary sinus, Cone beam Computed tomography.

ABSTRACT

Objectives: The aim of this study is to assess the relationship between the apices of the maxillary first molar roots and the maxillary sinus floor in a selected Saudi population using cone beam computed tomography (CBCT).

Methods: We analyzed 100 CBCT images from 50 patients, which were retrieved from the archives of the Oral Radiology Department of Riyadh Colleges of Dentistry & Pharmacy (RCsDP), Riyadh, Saudi Arabia. Forty-three images were of men and 57 of women (age, 11–56 years). They were analyzed using the software available with the CBCT machine. The roots were grouped as follows: Class 0: distance (d) = 0 mm; Class 1: 0 mm < d < 2 mm; Class 2: 2 mm ≤ d < 4 mm; Class 3: 4 mm ≤ d < 6 mm, Class 4: d ≥ 6 mm Means, standard deviations and percentages were calculated for all left and right molars. T-tests were used to compare measurements between right and left sides and between male and female patients.

Results: Statistical analyses revealed that class 1 roots had the highest prevalence. Their percentage was the highest among palatal roots (60.6%), followed by distobuccal roots (53.5%), and mesiobuccal roots (48%). Spearman's correlation coefficient showed the presence of a correlation between age and first molar root categories in case of the MB root.

Conclusions: The palatal root is the nearest to the sinus lift among all maxillary first molar roots. Clinicians should be aware of the anatomical details of the apices of the maxillary first molar roots especially the palatal root and the maxillary sinus floor while performing any surgical intervention.

INTRODUCTION

The first stage of the paranasal sinuses is maxillary sinus which develop, and the growth ends with the eruption of the third molars approximately at 20 years of age ^[1]. The maxillary sinus is a pyramidal cavity, and its base lies on the nasal antral wall while the tip extends to the zygomatic bone. Its estimated average volume is 15 cc ^[2]. The inferior sinus wall is a curved structure which is formed by the lower medial wall at 3rd position, the buccoalveolar wall, and the floor is formed by the alveolar process of the maxilla. The extension of the sinus in adult is variable ^[3].

The first molar is the first permanent tooth to erupt ^[2], and since the inferior wall of the maxillary sinus is curved and not flat, its topography in relation to the roots of first molar varies according to an individual's age, size and degree of pneumatization of the maxillary sinus, and the state of dental retention ^[2].

Decrease in the thickness of the bone between the roots of first molar and the inferior wall of the maxillary sinus might predict iatrogenic perforation of the sinus floor [4-6]. Furthermore, proximity of the root to the sinus floor may lead to spreading of odontogenic infection originating in the maxillary molars [7]. It is essential for clinicians to be aware of the exact relationship between the roots of first molar and the maxillary sinus floor.

Compared with standard medical computed tomography (MDCT), cone beam computed tomography (CBCT) may be recommended as a dose-sparing technique for dentomaxillofacial imaging. According to the International Commission on Radiological Protection (ICRP 2007) a standard dental protocol scan with MDCT is 1.5 to 12.3 times greater than that from a comparable medium-field of view dental CBCT scan [8,9].

The primary aim of this study was to assess the relationship between the apices of the maxillary first molar roots and the floor of the maxillary sinus in a selected Saudi population using CBCT [10].

MATERIALS AND METHODS

Fifty patients were studied, forming 100 cases (right and left side for each patient) of CBCT images retrieved from the archives of Oral Radiology Department of Riyadh Colleges of Dentistry & Pharmacy (RCsDP), Riyadh, Saudi Arabia. The study was approved by the Ethical Committee of the Research Center of RCsDP. Informed, written consent was obtained from each patient prior to imaging, including a clause for using the images for research purposes. Patients were classified into five age categories: Cat. 1 (11-20 years), Cat. 2 (21-30 years), Cat. 3 (31-40 years), Cat. 4 (41-50 years) and Cat. 5 (51-56 years).

Only firstmaxillary molars without apical periodontal infection, periodontal pockets and inflammation of maxillary sinus were included in the study.

All images were scanned using a CBCT machine (Galileos, Sirona) and CBCT images were analyzed using software. Images were obtained at 85 kV, 5-7 mA and 14 s with a voxel size of 0.3 mm, F.O.V15x15x15, (Sirona, Germany). An oral radiology specialist will examine all the images.

On cross sectional images, lines were drawn between the deepest point of the maxillary sinus floor and the root tips of the maxillary first molar, and the distance is measured using built-in measurement tools. Images were grouped, based on the distance measured between the root tips and the maxillary sinus floor as follows: Class 0: distance (d) = 0 mm; Class 1: 0 mm < d < 2 mm; Class 2: 2 mm ≤ d < 4 mm; Class 3: 4 mm ≤ d < 6 mm, and Class 4: 6 mm ≤ d [1] (Figures 1-5).

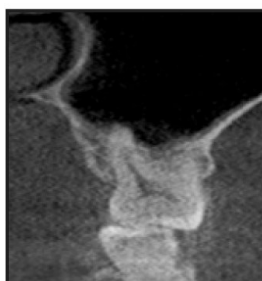

Figure 1. Class 0 relationship between the maxillary first molar palatal root and the sinus floor.

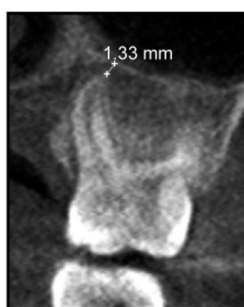


Figure 2. Class 1 relationship between the maxillary first molar palatal root and the sinus floor (1.33 mm distance).

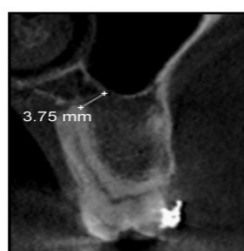

Figure 3. Class 2 relationship between the maxillary first molar disto-buccal root and the palatal floor (3.75 mm).

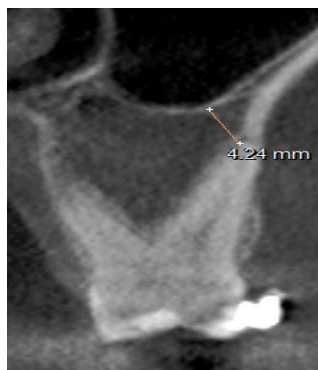

Figure 4. Class 3 relationship between the maxillary first molar mesio-buccal root and the sinus floor (4.24 mm).

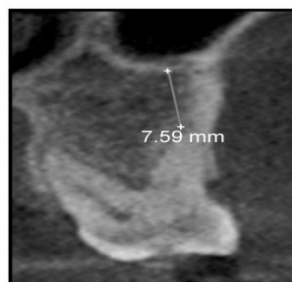


Figure 5. Class 4 relationship between the maxillary first molar disto-buccal root and the sinus floor (7.59 mm).

An inter-rater reliability analysis using the Kappa statistic was performed to determine consistency among raters.

Statistical analysis was performed using SPSS program version 20 (IBM SPSS Statistics for Windows, Armonk, NY, IBM Corp), where descriptive analysis, frequency, mean and standard deviations and percentages were calculated for all right and left first molars. Analysis of variance (ANOVA) was used to compare between the measurements of left and right sides and between female and male patients. A p-value < 0.05 was considered statistically significant.

RESULTS

Fifty patients were studied, forming 100 cases where 78% of the cases were from the right side of the face, while 22% were from the left side.

The inter-rater reliability was Kappa = 0.67 (p < 0.000), which is considered a substantial degree of agreement.

The frequency, mean, minimum, maximum and standard deviation for each variable (**Table 1**).

Table 1. Representing statistics of variables examined including the Mesio-buccal root apex (MB), the disto-buccal root apex (DB), and the palatal (P).

	MB	DB	Palatal
N	100	100	100
Mean (mm)	1.6	1.7	1.5
Std.Deviation	1.5	1.3	1.7
Minimum (mm)	0.0	0.0	0.0
Maximum (mm)	10.0	6.2	11.3

The relationship between gender, side (Right, Left) and distances measured at the apices of the 3 roots (**Table 2**). There was no significance between male and female in the distance of measured values (T-test, p > 0.05).

Regarding the different classes, class 1 showed the highest prevalence. The palatal root had the highest percentage of class 1 (60.6%), followed by the distobuccal (DB) root (53.5%), then the mesiobuccal (MB) root (48%). Class 2 was the second most prevalent class, where the highest percentage was in the MB root followed by the DB root and finally the palatal root. The prevalence of different classes in the study sample is demonstrated in **Figure 6**.

Table 2. Relationship between gender, side, and first molar roots analyzed by ANOVA.

Roots	Variables	N	Distance from maxillary sinus floor (Mean ± SD (mm))	F	p-value
MB	Male	43	1.4 ± 1.2	1.29	0.26
	Female	57	1.7 ± 1.7		
DB	Male	43	1.7 ± 1.1	.018	0.89
	Female	57	1.6 ± 1.4		

Palatal	Male	43	1.3 ± 1.2	0.97	0.33
	Female	57	1.7 ± 1.9		
MB	RT	78	1.6 ± 1.6	0.80	0.37
	LT	22	1.3 ± 1.2		
DB	RT	78	1.7 ± 1.3	0.38	0.85
	LT	22	1.6 ± 1.1		
Palatal	RT	78	1.6 ± 1.8	0.73	0.39
	LT	22	1.3 ± 1.1		

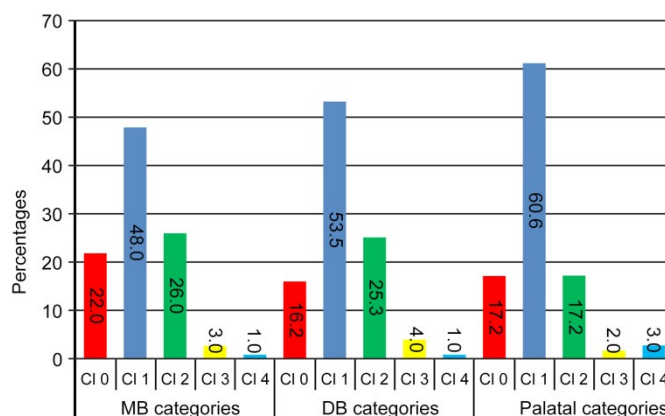


Figure 6. Distance (mm) between maxillary first molar roots and maxillary sinus floor in men and women. (MB: Mesiobuccal; DB: Distobuccal).

When relating the different age categories to first molar roots, in the MB and DB categories the minimal distance was in the age category 11-20 years, (0.94 ± 0.14 mm, and 1.06 ± 0.13 mm) respectively. The longest distance for the MB root was for the age category 41-50 years, (1.875 ± 0.28 mm), while for the DB root, the longest distance was in the 31-40 year category, (1.58 ± 0.23 mm). The age category 51-56 years showed the least distance among the palatal root categories (0.66 ± 0.47 mm), while the age category 31-40 years showed the highest distance (1.58 ± 0.24 mm) (**Figure 7**).

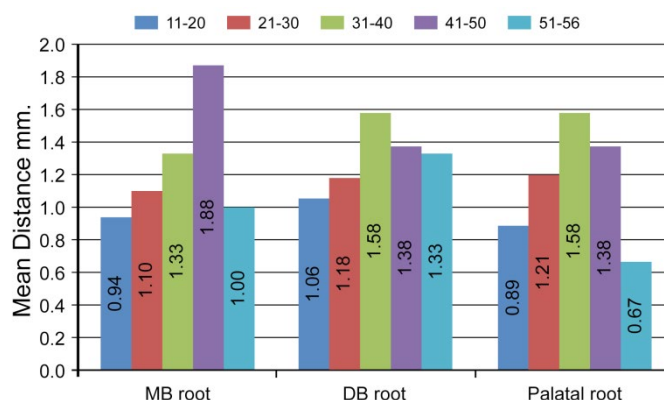


Figure 7. Prevalence of different classes in the mesiobuccal root (MB), the distobuccal root (DB) and the palatal root (P).

When assessing possible associations between first molar roots categories and different age categories using Spearman's correlation coefficient, the highest correlation was found between age categories and the MB root ($\rho=0.21$, $p=0.03$).

DISCUSSION

In this case, the anatomical relationship between the floor of the maxillary sinus and the apices of the first permanent molar roots was assessed in a selected sample of the Saudi population. Both left and right sides of each patient were evaluated separately. The knowledge of roots' proximity to the maxillary sinus can act as a predictor of perforation of the maxillary sinus during periapical surgery of maxillary molars [2]. Also, the closeness of the roots to the maxillary sinus may lead to maxillary sinusitis during root canal treatment and even periodontitis as reported by Huang and Brunsvold [11].

The utilization of CBCT technology assisted the study of this relationship, by providing accurate linear measurements of distances in images that are free from superimposition or distortion [12].

Accordingly, and based on the classification of Didilescu et al. [2] in the selected study group the highest percentage (60.6%) was for class 1, and mainly related to the palatal root followed by the MB root then the DB root.

Our findings differ from those of Didilescu et al. in their study in the Romanian population, they found that the most prevalent

class was class 0 in the palatal root, followed by the DB root ^[2]. In addition, our findings are contrary to those of Kilic et al. ^[13]; in their study on a selected group from the Turkish population, they found that the DB root was closest to the maxillary sinus floor, followed by the MB root, then the palatal root. Anatomically, three teeth describe to be in close proximity of the sinus floor: the second maxillary premolar, the first maxillary molar, and the second maxillary molar. Among these, the first maxillary molar roots were in direct relationship with the maxillary sinus floor. The roots of the second molars (especially the mesio-buccal roots), followed by the first molars (especially the buccal roots), third molars, second premolars and first premolars have the closest proximity to the sinus floor ^[14]. In other study the first premolar root tip was found to be the farthest, and the second molar buccomesial root tip was found to be closest to the sinus floor on both right and left sides ^[15]. Similarly, in another study involving a Korean population, the most prevalent location of the root tips of the first molar was their projection into the maxillary sinus, constituting 54% of the case was studied. The DB root was the closest, while the palatal root was farthest ^[6]. The palatine roots have been shown to be closer to the antral floor than to the palate and in close proximity to the maxillary sinus in 20 percent of cases. This location complicates a surgical approach through the sinus, so that palatinal access is usually required ^[7].

In our study, the second most prevalent class was class 2 (26%) but with a different sequence, where the MB root was the nearest, followed by the DB root and then the palatal root. This finding is contrary to the finding of Di dilescu et al. who found that the second prevalent class was class 1, while the closest root was the DB root ^[2]. If the patients need endodontic surgery of the first maxillary molar, the surgeon should know the oroantral communication that may occur. It has been proven that conventional periapical radiographs cannot be used as predictors for perforation of the maxillary sinus during periapical surgery of maxillary premolars and molars ^[16]. Therefore, in these cases, preoperative CBCT scan is highly recommended.

When comparing between the right and left sides, although, there was no statistically significant difference between sides, the left side showed a closer relationship to the floor of the maxillary sinus than the right side. This finding is in accordance with the finding of Kilic et al. ^[13]. Because of the anatomical relationship that exists between the maxillary first molar roots and the sinus floor, endodontic surgery of the first molar may be safer in Saudi individuals after verification of the exact root location by CBCT than in other populations. Nevertheless, the incidence of accidental oroantral communication that can allow bacteria from infected periapical tissue, resected root tips, or bony drilling dust into the sinus and cause acute or chronic sinusitis will be less frequent in this population.

Regarding different age categories, the distance between roots' tips and the floor of the maxillary sinus gradually increased until reaching 31-40 years age category, then the distance gradually decreased in both the DB roots and palatal roots. Conversely, in the MB root the distance gradually increased until the 41-50 years age category, then started to decrease. According to Spearman's correlation coefficient, the correlation between age category and the MB root was highest. This finding differs from the finding of Arijji et al. who found that the distance increased until the age of 20 then gradually decreased ^[17]. the maxillary 1st molar tooth not only represent a good support for maintaining the sinus bone floor, but also, if healthy may stimulate bone apposition throughout life ^[7].

CONCLUSION

The palatal root is the nearest to the sinus floor among all maxillary first molar roots. Clinicians should be aware of the anatomical details of the apices of the maxillary first molar roots especially the palatal root and the maxillary sinus floor while performing any surgical intervention.

CONFLICT OF INTEREST

Authors deny any conflict of interest.

The Source of Funding

This project was funded by Riyadh Colleges of Dentistry and Pharmacy.

REFERENCES

1. Misch CE. Contemporary implant dentistry. 2nd ed. St.Louis: CV Mosby Co. 1999;76-194.
2. Didilescu A, et al. Morphometric analysis of the relationships between the maxillary first molar and maxillary sinus floor. Open Journal of Stomatology. 2012;2:352-357.
3. McGrowan DA, et al. The Maxillary Sinus and its Dental Implications. 1st ed. London: Wright Co. 1993;1-25.
4. Laine F. Diagnostic imaging of the maxillary sinus. Oral and Maxillofacial Surgery Clinics of North America. 1999;11:45-67.
5. Hauman CH, et al. Endodontic implications of the maxillary sinus: a review. International endodontic journal. 2002;135:127-141.
6. Jung YH and Cho BH. Assessment of the relationship between the maxillary molars and adjacent structures using cone beam computed tomography. Imaging science in dentistry. 2012;42:219-224.

7. Kilic C, et al. An Assessment of the Relationship between the Maxillary Sinus Floor and the Maxillary Posterior Teeth Root Tips Using Dental Cone-beam Computerized Tomography. *European Journal of Dentistry*. 2010;4:462-467.
8. Fuhrmann R, et al. Radiological assessment of artificial bone defects in the floor of the maxillary sinus. *Dentomaxillo facial radiology*. 1997;26:112–116.
9. Valentin J. The 2007 Recommendations of the International Commission on Radiological Protection. ICRP Publication 103. *Annals of the ICRP*. 2007;37:1-34.
10. Ludlow JB and Ivanovic M. Comparative dosimetry of dental CBCT devices and 64-slice CT for oral and maxillofacial radiology. *Oral surgery, oral medicine, oral pathology, oral radiology, and endodontics*. 2008;106(1):106-114.
11. Huangand CH and Brunsvold MA. Maxillary sinusitis and periapical abscess following periodontal therapy: A case report using three-dimensional evaluation. *Journal of Periodontology*. 2006;77:129-134.
12. Stuchi B, et al. Maxillary sinus and posterior Teeth: Accessing lose relationship by Cone-beam Computed Topographic Scanning in a Brazilian Population. *Journal of endodontics*. 2013; 39:748–751.
13. Kilic C, et al. An assessment of the relationship between the maxillary sinus floor and the maxillary posterior teeth root tips using dental cone-beam computerized tomography. *European Journal of Dentistry*. 2010;4:462-467.
14. Abubaker AO. Applied anatomy of the maxillary sinus. *Oral and Maxillofacial Surgery Clinics of North America*. 1999;11:1-13.
15. Roque-Torres GD, et al. 2D and 3D imaging of the relationship between maxillary sinus and posterior teeth. *Braz. J. Oral*. 2015;14(2):141-148.
16. Oberli K, et al. Periapical surgery and the maxillary sinus: Radiographic parameters for clinical outcome. *Oral Surgery, Oral Medicine, Oral Pathology, Oral Radiology, and Endo-dontic*. 103: 848-853.
17. Arijji Y, et al. Age changes in the volume of the human maxillary sinus: A study using computed tomography. *Dento Maxillo Facial Radiology*. 1994;23:163-168.