

Silicone Prosthesis For Multiple Finger Amputation — A Case Report

Dr. R. Ravichandran

Professor of Prosthodontics, Government Dental College and Hospital, Trivandrum, Kerala, India

Case Report

Received: 05/07/2016

Accepted: 22/08/2016

Published: 29/08/2016

*For Correspondence

Dr. R. Ravichandran , Professor of Prosthodontics, Government Dental college and Hospital, Trivandrum, Kerala, India

E-mail: drravichandran11@yahoo.com

Keywords: Amputation, Esthetics, Silicone prosthesis.

INTRODUCTION

Traumatic injury to hand may result in complete or partial amputation of fingers which will result in functional deficiency, disfigurement and social stigma. The causes for finger or hand loss can be either due to trauma, congenital absence or malformation. Amputation of finger leads to catastrophic physical, psychological and economic burden to an individual as well. Rehabilitation of amputated finger is of an utmost importance as it restores the natural esthetics and thereby eliminates the psychological and emotional stress of the patient. The success of rehabilitation in an amputated finger depends on factors like the level of amputation, the amount of remaining bone, the tissue status and the number of fingers involved etc. Although microsurgical reimplantation may correct the injured or traumatically amputated finger, an esthetic prosthetic rehabilitation should be a treatment option when a surgical reconstruction is contraindicated at times. Moreover this provides a good psychological support along with a kind of passive function for the fingers in such patients. This paper present a case report of a patient with multiple amputated finger (**Figure 1**) who was rehabilitated using custom made silicone finger prosthesis. These silicone prosthesis are made to match the skin colour, provides life like appearance, good retention, and comfort for the patient^[1]. Here the scilicons used for the fabrication of prosthesis was room temperature vulcanised or RTV scilicons. The advantage of the material include chemical inertness, ease of staining, flexibility, elasticity and high edge strength which makes the prosthesis more durable without much changes in color and fit. Hence the scilicons are always preferred to other materials like acrylic, porcelain, polyurethenes etc. (**Figure 2**).

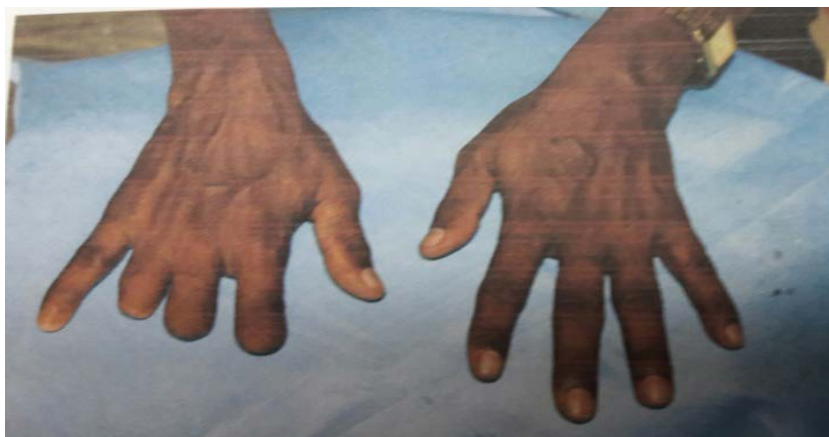

Figure 1: Patient's hand with amputated fingers.

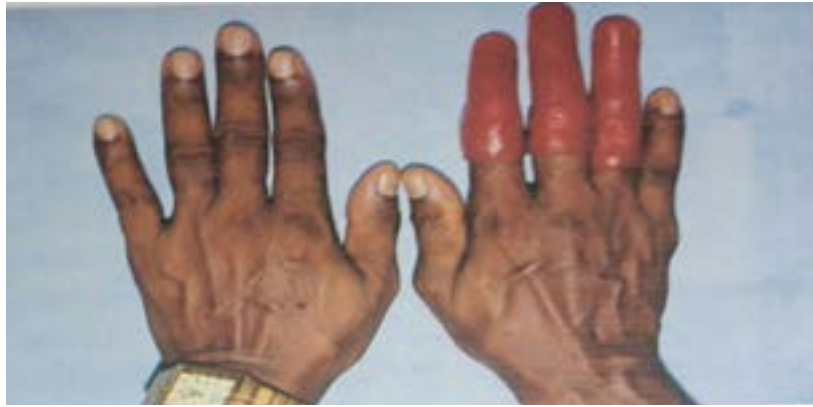

Figure 2: Patient hand with wax trial prosthesis.

CASE REPORT

A 52 yr old male whose middle and ring finger of his right hand was lost at the level of interphalangeal joint. He had a history of trauma to his right hand while working on mechanical metal cutting lath 10 months back. During the physical examination it was noticed that middle finger amputation was done at the level of the lower third of the middle phalanx and in the ring finger at the level of junction of the proximal phalanx and the middle phalanx. The fingers had surgical scar and movements were restricted. Patient was explained the different treatment option including implant retained finger prosthesis ^[2]. But due to financial constraints and longer duration of treatment patient didn't opt for implant retained prosthesis but for natural glove type silicone finger prosthesis.

PROCEDURE

Before impression making, the patient's hand with missing fingers was lubricated with a thin layer of petroleum jelly and the area around the hand was boxed ^[3]. Then a thin mix of irreversible hydrocolloid impression material was placed over the palmer side first and then the dorsal side. The patient was instructed to keep the hand in the normal resting position while impression making. Impression was poured in type III dental stone and working model of hand was obtained. For making wax pattern impression of the unaffected hand was taken and into which molten modeling wax was poured. The set wax pattern was then hollowed from inside by sculpting. Tooth coloured acrylic resin material was used to fabricate custom made acrylic nail for the prosthesis ^[4]. Colour and shade matching was done with the nail of adjacent fingers and integral half-moons, white margins and other details were incorporated. The size and position of the acrylic nail was established and the nail bed was prepared, where the custom made acrylic nail was adapted into place. The wax patterns were tried on the patient's hand and the length and fit was verified. The shade matching of artificial nail was also verified. Approval from the patient was taken and then the artificial nail was removed ^[5]. To improve the retention of the silicone prosthesis, the circumference of the finger stumps were reduced accurately by 1 mm and vertical grooves were made to create vacuum chambers in order to provide a snug fit of the prosthesis and also aid in vacuum retention. The wax patterns were invested separately in a type III dental stone using three pour techniques to facilitate an easy packing of silicone and separate colour matching for dorsal and ventral surfaces. This mold was dewaxed by immersing in a boiling water bath and separating medium was applied. The Silicone and pigments were mixed intrinsically to match patient's skin. Colour matching of the dorsal and ventral surface was done separately in natural light. After getting the desired shade the silicone material was packed into the mold and light pressure was applied to remove excess material. After polymerization, the prostheses were carefully retrieved from the mold and finishing was done. For the silicone prosthesis a slit was made along the crease on the nail bead area, where nail is to be inserted. The excess 2 mm nail portion was inserted into the slit and a cyanoacrylate adhesive was applied on the under surface of the nail for bonding with the silicone surface and placed back on the mold to achieve a stronger bond to the nail bed ^[6]. The final prosthesis was inserted on the residual stump and the fit and colour matching was evaluated. The patient was demonstrated about the use and instructions were given about maintenance of the prosthesis. For prosthesis evaluation, the patient was asked to return on day 1 and 7 for follow-ups. There after a 3 month follow-up was done and it was noted that the patient had no complaints and was satisfied about esthetics and comfort of the finger prosthesis ^[7].

DISCUSSION

According to Pilley ^[8] when a surgical reconstruction of lost finger is contraindicated, unsuccessful or unavailable, a prosthesis can provide or offer a great psychological help for the patient. A precisely fitting prosthesis can improve function by restoring normal length, providing opposition for the remaining digits, maintaining sensitivity through a thin lamina, protecting a sensitive stump, transmitting pressure and sense of position for activities such as writing or typing etc ^[9]. Both the psychological and func-

tional effects of the prosthesis enhance rehabilitation by helping patients to adjust to their loss and by permitting a more normal professional and social life. The essential characteristics of the finger prosthesis were described by Pillet as the prosthesis must be of high quality, both technically and aesthetically. It must also emulate the digits of the opposite hand beyond recognition. The skin must correspond to the normal skin in all details and match the color as precisely as possible. The material of the prosthesis must be strong and repairable once damaged. It must not stiffen at low temperatures within the normal climatic range and must also be heat resistant as well. Material must not be stained by ordinary agents such as newsprint and, if soiled, must be easily cleansable by washing in water with a mild detergent and should not irritate the skin on contact ^[10]. As silicon fulfills all the needed requirements Buckner et al. stated that the acceptance rate of individually sculpted custom made silicone prosthesis has been much higher than any other one. Apart from silicon acrylic resins, enameled porcelain, polyurethanes are also in use as extra oral prosthetic materials. Acrylic resin is popular because of its ease in characterisation, economy and durability. But its hardness makes it unacceptable and uncomfortable for the patient. A clear or translucent silicon known to be compatible with all intrinsic and extrinsic coloring systems used for such prosthesis. But in case of other materials these systems will fade off in a faster rate. Among the retentive devices used for the prosthesis, implants and adhesives are used most effectively with silicon than with acrylics. Moreover specially designed extra oral titanium implants including mini implants are being tried to make the treatment more realistic and natural in case of ear, eye and nose prosthesis (**Figures 3 and 4**).




Figure 3: Pigments and Color matching with silicon.

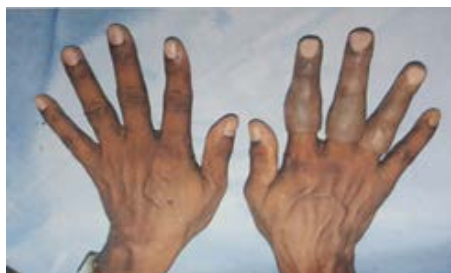

Figure 4: Completed silicon finger prosthesis.

CONCLUSION

It is of utmost importance to rehabilitate the patient with amputated finger to restore the form and esthetics in order to eliminate the trauma generated by the dysfunction and to provide an efficient psychological help. When the option of surgical reconstruction is ruled out, the prosthetic rehabilitation with high quality esthetic silicone finger prosthesis using modern prosthetic designs, fabricated with acumen, can be life like and hence eliminating the psychological and social stigma of an individual.

REFERENCES

1. Angadi, et al. Bhandari. *Prosthetics and Orthotics International*. 2010;34(4):488-449.
2. Kamble VB, et al., *Silicone finger prostheses for single finger partial amputations: Two case reports*. *Indian Journal of Dentistry*. 2012;03:10.
3. Pilley MJ and Quinton DN. *Digital prostheses for single finger amputations*. *J Hand Surg*. 1999;24(5):539-541.
4. Jean Pillet, et al. *Library Aesthetic Restoration*. *Atlas of Limb Prosthetics: Surgical, Prosthetic, and Rehabilitation Principles: Partial-Hand Amputations*.
5. Buckner H. *Cosmetic hand prosthesis-a case report*. *Orthot Prosthet*.1980;34(3):41-45.
6. Livingstone DP. *The D-Z stump protector*. *Am J Occup Ther*.1988;42:185-187.

7. Aydin C, et al. Implant-retained digital prostheses with Custom designed attachments: A clinical report. *The Journal of Prosthetic Dentistry*. 2007;97(4):191-195.
8. Pillet J. Esthetic hand prostheses. *J Hand Surg Am*. 1983;8:778-781.
9. Michael JW and Buckner H. Options for finger prosthesis. *J Prosthet Orthot*. 1994;6(1):10-14.
10. Michael EL and Robert WH. Optimal circumference reduction of finger models for good Prosthetic fit of thimble-type prosthesis for distal finger amputations. *Journal of Rehabilitation Research and Development*. 2001;38(2):273-279.