

Aetiormorphological and Demographic Variations of Post Fever Retinal Complications Following Pathogenic

G Nageswar Rao¹, G Prasanna², Huma Rizwan³, Sweta Pal³, Silpa Sabnam³ and Arttatrana Pal^{4*}

¹Department of Ophthalmology, Kalinga Institute of Medical Sciences, KIIT, Bhubaneswar, India

²Department of Gynaecology, Kalinga Institute of Medical Sciences, KIIT, Bhubaneswar, India

³School of Biotechnology, KIIT University, Bhubaneswar, India

⁴Department of Zoology, School of Life Sciences, Mahatma Gandhi Central University, Motihari, India

Research Article

Received date: 26/02/2018

Accepted date: 01/06/2018

Published date: 07/06/2018

*For Correspondence

G Nageswar Rao, Department of Zoology, School of Life Sciences, Mahatma Gandhi Central University Bihar, Motihari, Bihar-845401, India.

E-mail: arttatrana@yahoo.com

Keywords: Microbial infection, Feverish sickness, Retinal complications, Vision loss, Steroids

ABSTRACT

There are several factors that contribute to the development of retinal complications following feverish sickness due to pathogenic infections. However, information on pathogenic-induced feverish sickness trigger retinal complications is fragmentary. Here we undertook this study to analyze the clinical manifestation of febrile syndrome retinal complications following with/without pathogenic infections. A complete ophthalmic examination was performed in 39 patients soon after they diagnosed with acute neuroretinitis, vasculitis, and neurosensory detachment in one or both eyes. Retinal complications were diagnosed based on clinical history. Fundus fluorescein angiography (FFA) showed a solitary or multiple patches of retinitis at the posterior pole and exudation at the macula with serous macular detachment. Early FFA showed hypofluorescence of the lesion, which leads to the hyperfluorescence in the late phase. Optical coherence tomography (OCT) showed inner retinal hyperreflectivity and central macular thickness with foveal detachment and shadowing. Initially, patients were treated with methylprednisolone, followed by oral prednisolone. All patients showed improvement in vision with unilateral cases to an average of 6/12 and bilateral cases to an average of 6/24. Patients also showed resolution of neuroretinitis, macular edema and serous detachment in subsequent follow-up. In summary, post fever retinitis and its related complications with/without pathogenic infections as a condition manifested after onset of fever. Irrespective of the cause of the fever, clinical presentation of patients was similar with inner and outer retinitis at the posterior pole and a favourable response to steroids, suggesting possible remedies against these retinal complications.

INTRODUCTION

Pathogenic infections by viruses, bacteria, fungi, and parasites are potentially caused devastating ocular manifestations. Many lines of study revealed that ocular manifestations occurred after fever incidents includes conjunctival congestion, uveitis, episcleritis, neuroretinitis, retinitis, vitreous haemorrhage, retinal haemorrhage and detachment, stellate maculopathy, pigmentary retinopathy, optic neuritis, internal or external ophthalmoplegia, orbital haemorrhage and dacryoadenitis^[1-3]. Fever due to pathogen infection is the main cause frequently observed in infectious retinitis patients. Retinitis is characterized by progressive damage and whitening of retina, which progresses along the retinal blood vessels, often associated with intra-retinal hemorrhages and hard exudates and finally leads to the permanent vision loss to the infected subjects. Apart from retinitis, patients also have varied complications in posterior segment including focal and multifocal patches of retinitis, possible optic nerve involvement, serous detachment at the macula, macular edema and localized involvement of the retinal vessel. More importantly, in post fever conditions after pathogenic infections affect retina differently from patient to patient depending on different factors like age, location, pathophysiological conditions and immunity of the patients^[4]. Typically, symptoms can emerge quickly or slowly in

retinitis subjects depend upon the pathogenic agents and its post fever effect.

Several studies have demonstrated that a number of microbes were main source of retinal complications. Specifically, herpes simplex virus (HSV) and herpes zoster virus (HZV) can cause critical retinal complications such as retinal necrosis and progressive outer retinal necrosis^[5,6]. Similarly, cytomegalovirus (CMV) is in the same viral family and can cause retinitis in patients with compromised immune systems^[7,8]. Chikungunya is an acute febrile syndrome characterized by high-grade fever with chills, myalgia, headache, photophobia, skin rash, and severe disabling arthritis^[9,10]. Apart from viral infections, retinal complications also associated with cat-scratch disease from *Bartonella* species carried by cat fleas, with Lyme disease from *Borrelia burgdorferi* carried by Ixodes ticks, with syphilis caused by *Treponema pallidum* or tuberculosis caused by *Mycobacterium* species^[11]. Most importantly, some patients harbor infection elsewhere in their bodies, which eventually seeds the eye and trigger retinal damage. These endogenous factors intraocular infections may be bacterial, but may also be fungal, from yeasts like *Candida* species or molds like *Aspergillus* species^[12]. Moreover, some parasites also cause infectious diseases like toxoplasmosis, toxocarasis, and diffuse unilateral subacute neuroretinitis^[13]. Typhoid fever is caused by *Salmonella typhi* and can rarely affect the retina either by direct infection or by immune-mediated mechanism^[14]. Earlier report by Duke-Elders and Perkins^[15] demonstrated that typhoid-related uveal complications including iritis, retinal hemorrhage, choroiditis, endophthalmitis and panophthalmitis. Studies have also revealed that late-onset endogenous endophthalmitis post-typhoid fever resolution^[16,17].

Many lines of studies have demonstrated the post fever ocular abnormalities after pathogenic infections are optic neuritis, papillitis, neuroretinitis, panuveitis, non-granulomatous anterior uveitis, and retinitis^[18-21]. Some patients with 1-6 weeks post fever due to pathogen infections showed ocular manifestations characterized by blurred vision and having focal and multifocal patches of retinitis, possible optic nerve involvement, serous detachment at the macula, macular edema and localized involvement of the retinal vessel^[4]. Some cases vision was blurred by inflammatory haze within the eye and by involvement of specific retinal areas that give central vision. Besides, the inner retinal layers including inner limiting membrane, retinal nerve fiber layer (RNFL), ganglion cell layer (GCL), inner plexiform layer (IPL), and inner nuclear layer measured by manual methods were widely different, and RNFL thickness was dramatically different in individuals in different pathophysiological conditions^[22-24]. Recently, several studies have demonstrated that ocular abnormalities can occur following a feverish illness due to pathogenic infections. However, information on retinal complications following with/without pathogenic infections are fragmentary. Here we undertook this study to analyze the clinical manifestation of febrile syndrome retinal complications with or without pathogenic infections by multimodal imaging techniques like fundus, FFA, and OCT following systemic corticosteroid administration.

MATERIALS AND METHODS

This was a retrospective study of 39 patients attending the Department of Ophthalmology, Kalinga Institute of Medical Sciences (KIMS), KIIT, Bhubaneswar and Vision Care-Centre for Retina, Bhubaneswar, India between January 2015 and February 2018. Informed consent was obtained from all study patients. Patients of pathogenic caused post fever retinal complications in one eye or both eyes were diagnosed based on clinical history and complete ophthalmic examination, including visual field testing, measurement of best-corrected visual acuity (BCVA; Snellen chart), color vision (Ishihara pseudoisochromatic color vision plates), funduscopy appearance, FFA, central visual field, pupillary reaction by relative afferent pupillary defect (RAPD), and visual field (Humphrey field analyzer), as well as intraocular pressure by applanation tonometry, indirect ophthalmoscopy of the dilated fundus, noncontact tonometry, slit-lamp bio-microscopy of the anterior and posterior segments, and visual evoked potentials were performed in all patients. Optical coherence tomography evaluation High-definition (HD)-OCT (Cirrus high-definition 5000 OCT) with an axial resolution of 5 mm was performed on all patients in one eye or both eyes. Cross-section images of 6 mm horizontal and vertical scans through the central fovea were obtained. A macular cube 512 × 128 scan was obtained by Cirrus H-OCT to obtain the central fovea thicknesses (CFT). However, those patients with media opacity, preexisting macular or optic nerve pathology or any preexisting retinopathy were excluded from this study.

Along with ophthalmic examination, other basic laboratory investigations were followed with patient history such as complete hemogram including total count, differential count, erythrocyte sedimentation rate, platelet count, and peripheral blood smear. Moreover, for the pathogenic infections laboratory investigations were followed with patient history such as blood culture, venereal disease research laboratory tests (VDRL), human immunodeficiency virus (HIV), Mantoux test, chest X-ray, toxoplasma immunoglobulin (Ig)G, Widal test, tuberculosis, chikungunya IgG/IgM, dengue IgG/IgM, and malaria parasite.

After complete review of diagnosis with pathogenic infection and post fever retinal complications all patients were treated with intravenous methylprednisolone initially 1 g/day for 3 days, followed by a daily dose of 1 mg/kg body weight of prednisolone for 2 weeks orally, thereafter reducing the dose of prednisolone over 4 weeks and tapered over a period of 6 weeks follow-up based on the clinical response. At each visit, BCVA, anterior and posterior segment evaluation, fundus photography, and OCT was performed. Clinical response was assessed based on BCVA, anterior and posterior segment findings, and OCT. Blood pressure, body weight, blood sugar, serum electrolytes, and electrocardiography were recorded before starting therapy. None of our patients had risk factors like hypertension or diabetes mellitus or a previous history of visual loss.

RESULTS

Demographic complications of all the patients with retinal complications associated with/without different pathogenic infection were diagnosed as per the patients' history. Both male and female patients of the study were in the age group of 20–60 years. Of the patients in the study, three patients (2 male and 1 female) presented infection with chikungunya with sudden onset decrease in vision in both eyes and pain on ocular movements in both eyes had a history of fever, headache, joint pain, and skin rash. Visual acuity in both the eyes was ranged from perception of light (PL) to visual acuity of 6/6 and BCVA in the normal eye was 6/6. Moreover, patient had pupillary abnormalities such as RAPD, unilateral optic neuritis with sluggish reaction of the pupil, discrete yellowish white deep retinal lesions on the posterior pole, and visual field (HFA FF 120) defect, including central, centrocecal, paracentral scotoma and peripheral constriction (**Figure 1A**). Slit-lamp examination revealed no evidence of inflammation in the anterior chamber. Intraocular pressure by applanation tonometry was 16 mmHg. Fluorescein angiography showed initial hypofluorescence (**Figure 1B**) and late hyperfluorescence (**Figure 1C**) of the lesion in patients before systemic steroid treatment. OCT scans at the time of presentation through the lesion showed irregularities in the IS and OS junction, cystic elevation of the outer plexiform layer (**Figure 1D**). Moreover, few eyes presented with bilateral optic neuritis (**Figure 1E**) and optic neuritis with para foveal outer retinitis patches (**Figure 1F**). All patients were treated with intravenous methylprednisolone 1 g/day for 3 consecutive days, followed by a daily dose of 1 mg/kg body weight of oral prednisolone for 2 weeks, thereafter reducing the dose of prednisolone over 4 weeks based on the clinical response. At the end of 4-6 weeks the BCVA was ranged from 6/9 - 6/6 and N6. Fundus examination revealed resolution of retinal complications (**Figure 1G-I**).

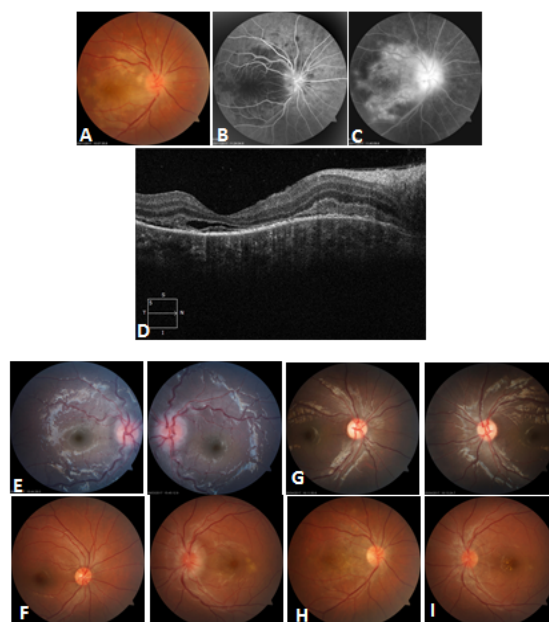


Figure 1: Fundus image and fundus fluorescein angiography (FFA) before treatment Unilateral fundus image showing optic neuritis and discrete yellowish white deep retinal lesions on the posterior pole (A). Fluorescein angiography showing initial hypofluorescence (B) and late hyperfluorescence (C) of the lesion in patients before systemic steroid treatment. Optical coherence tomography (OCT) showing irregularities in the IS and OS junction, cystic elevation of the outer plexiform layer (D). Bilateral optic neuritis (E) and optic neuritis with para foveal outer retinitis patches in left eye and right eye shows normal (F). Fundus image showing resolution of optic neuritis and para foveal outer retinitis patches (G-I).

Five patients (4 males and 1 female) presented past history of dengue fever (IgM antibodies) and subsequent complaints were joint pain, back pain, headache, and skin rash. Visual symptoms like blurring of vision in one eye or both the eyes were developed 10-15 days after the onset of the febrile period, which was reduced to counting fingers at 0.5 m, and mostly seen in the posterior pole of the fundus, manifesting as retinal hemorrhages, macular edema, central scotoma, foveolitis, and vasculitis. More importantly, Amsler grid test for the areas of scotomas corresponded to the areas of edema and the form of dot, blot, or flame-shaped hemorrhages. Interestingly, couple of eyes showed vascular sheathing and vasculitis association with macular hemorrhage (**Figure 2A-D**). Further, all eyes were examined by FFA, which mainly demonstrated the vascular occlusion or leakage and paravascular staining corresponding to the vasculitis. Vascular occlusions were observed in four eyes, and mainly consisted of vein occlusions bilaterally or unilaterally. Only one out of the ten eyes had seen arterial occlusion of the superotemporal macular branch unilaterally. There were 4 out of ten eyes presented with subconjunctival hemorrhage and retinopathy sparing the macula, stellar neuroretinitis, and retinal hemorrhages. OCT imaging of the macula had been employed in all eyes to evaluate retinal thickness and morphology. Moreover, both the eyes of one patient showed congested optic nerve heads with massive peridiscal hemorrhages with few macular exudation (**Figure 2E**). All patients were treated with intravenous methylprednisolone 1 g/day for 3 consecutive days, followed by a daily dose of 1 mg/kg body weight of oral prednisolone for 2 weeks, thereafter reducing

the dose of prednisolone over 4 weeks based on the clinical response. Every visit fundus photograph was documented. After 2 months of initiating treatment, there was an improvement in the BCVA 6/9 to 6/6, which was maintained on further visits. Fundus examinations revealed resolving lesions in both eyes (**Figure 2F**) and OCT showed resolution of the serous macular detachment. Moreover, repeat Humphrey visual field analysis showed improvement of scotomas of the patients.

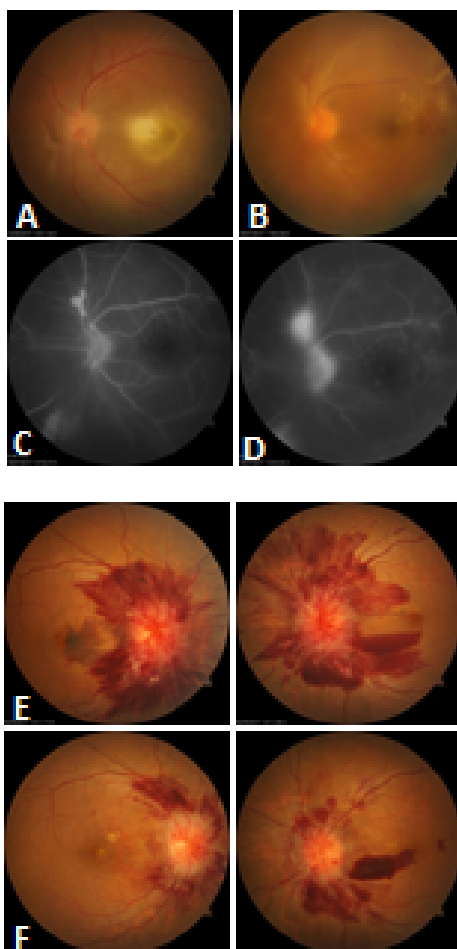


Figure 2: Fundus image before treatment showing central retinitis patch with foveal detachment (A), vascular sheathing and vasculitis association with macular hemorrhage (B). FFA images showing vascular occlusion or leakage and paravascular staining corresponding to the vasculitis (C,D). Bilateral fundus image showing congested optic nerve heads with massive peridiscal hemorrhages with few macular exudation (E). Bilateral fundus image showing resolving lesions in both eyes after treatment (F).

Fifteen patients (9 males and 6 females) presented past history of typhoid fever with sudden painless decreased vision in the one eye or both the eyes associated with floaters 3-5 weeks prior to presentation for which Widal test was performed to confirm diagnosis. Patients were subsequently started on oral Ofloxacin 400 mg twice daily for 2 weeks following which fever subsided. However, patients began to experience decreased in vision 3-5 weeks after the onset of treatment. There was no known history of life style disease complications or hypertension or any other complications meanwhile. On ocular examination BCVA in the affected eyes were varied from 2/60 to 6/12. Anterior segment findings were unremarkable with IOP being within normal range for both eyes. Colour vision by using Ishihara's pseudoiso-chromatic chart was defective in maximum eyes. Fundus examination showed white fluffy lesions along the superior arcades with superficial haemorrhages in around the macula with a macular star suggestive of retinitis (**Figure 3A**). The FFA revealed delayed arterio-venous transit time, which was suggestive of retinal arterial blockage (**Figure 3B**) and late leakage from the lesion (**Figure 3C**). Moreover, fundus examinations of few eyes were revealed clear media with normal looking disc and multiple whitish fluffy areas of deep retinitis and a large neurosensory detachment in the macular area (**Figure 3D**). The FAA revealed early hypofluorescence (**Figure 3E**) and late hyperfluorescence corresponds to the retinal lesions (**Figure 3F**). On OCT of few eyes underlying macular serous retinal detachment were prominent. This was seen as a highly reflective and disorganized inner retinal layer with back scattering and underlying serous retinal detachment on OCT (**Figure 3G**). More importantly, some eyes had clear media, normal disc and normal foveal reflex, isolated discrete cotton-wool spot superior to the disc and a nasal area of retinal venous sheathing. After diagnosis of post typhoid retinitis, patients were started on oral prednisolone 1 mg/kg body weight, which was tapered over 2 months along with monitoring of systemic and ocular health. Patient came for follow up every 2 weeks for 3 months. Every visit fundus photo was documented. After 2 months of initiating treatment there was an improvement in the BCVA ranged from 6/12 to 6/6, which was maintained on further visits.

Fundus examination showed resolution of the lesions including serous detachment, which was confirmed by OCT.

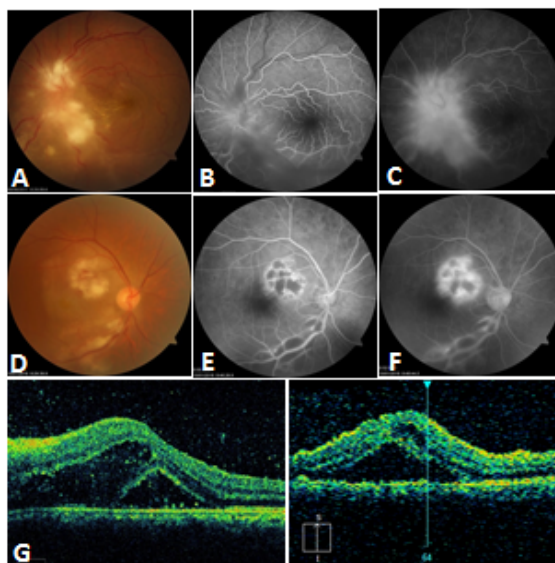


Figure 3: Fundus images showing white fluffy lesions along the superior arcades with superficial haemorrhages in and around the macula with a macular star (A). FFA images showing delayed arterio-venous transit time, which was suggestive of retinal arterial blockage (B) and late leakage from the lesion (C). Fundus images showing clear media with normal looking disc and multiple whitish fluffy areas of deep retinitis and a large neurosensory detachment in the macular area (D). FAA images showing early hypofluorescence (E) and late hyperfluorescence corresponds to the retinal lesions (F,F). Optical coherence tomography (OCT) showing macular serous retinal detachment (F), and inner retinal layer hyperreflectivity with back scattering on OCT (G).

Sixteen patients (10 males and 6 females) presented past history of fever with sudden, painless decreased vision in the one eye or both the eyes associated with retinal complications without any positive test of pathogenic infections. Initially, they had a fever for 10-15 days and initiated the treatment, which resolved the fever but they began to feel the sudden decrease in vision after the onset of treatment. There was no known history of diabetes mellitus or hypertension. At the preliminary ophthalmological examination the visual acuity was varied in one eye or both the eyes such as 2/60 to 1/60 and 6/60 to 6/18 respectively and intraocular pressure was normal in both eyes. The fundus examinations of 17 eyes showed retinitis patches, serous macular detachment, hypofluorescence and hyperfluorescence of the lesion (**Figure 4A-C**). The OCT scans at the time of presentation through the lesion showed increased hyperreflectivity with central macular thickness leads to the shadowing of the outer layers and foveal detachment in patients before oral steroid treatment (**Figure 4D**). In one of the patients found bilateral retinitis patches with involvement of macula in the right eye (**Figure 4E,F**). After diagnosis of post fever retinitis and related ocular complications, patients were started on oral prednisolone 1 mg/kg body weight, which was tapered over 8 weeks along with monitoring of systemic and ocular health. After 4-6 week follow-up the general symptoms were improved and the average visual acuity was 6/36 to 6/6. Every visit fundus photo was documented. Fundus fluorescein angiography and OCT scans after 4-6 week follow-up showed a recovery of retinitis patches. In few cases foveal pigment epithelial atrophy and thinning of the fovea noted.

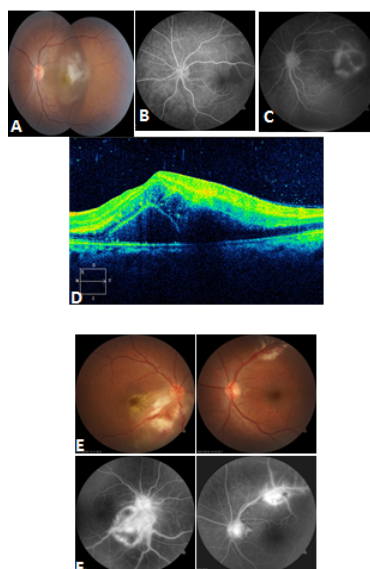


Figure 4: Fundus images and fundus fluorescein angiography (FFA) showing retinitis patches, serous macular detachment, hypofluorescence and

hyperfluorescence of the lesion (A-C). Optical coherence tomography (OCT) showing increased hyper reflectivity with central macular thickness (D). Found images and FAA showing bilateral retinitis patches with involvement of macula (E,F).

DISCUSSION

Ocular complications occurring post febrile illnesses trigger vision loss have been reported after several pathogenic infections and also in non-infectious immune disorders [25,26]. Also, many lines of studies have demonstrated that occurrence of post fever due to pathogenic infections played a major role in different ocular manifestations like non-granulomatous anterior uveitis, episcleritis, panuveitis, granulomatous anterior uveitis, optic neuritis, sixth nerve palsy, retrobulbar neuritis, retinitis with vitritis, neuroretinitis, keratitis, central retinal artery occlusion, multifocal choroiditis, exudative retinal detachment and secondary glaucoma [27]. The fever mediated retinal complications are the retinal diseases causing damage to photoreceptors of retina. The disease is characterized by floaters or decreased vision or blurred vision. Importantly, the interval between the onset of fever and retinal complications were approximately 2 to 3 weeks. This impediment favours the hypothesis that the ocular lesions could be an immune mediated process rather than a direct pathogenic infection.

In our study, we provided the clinical description of 3 patients suffering from post-fever retinitis and other retinal complications after chikungunya infections. The manifestations include bilateral focal or multifocal patches of retinitis, which was associated with macular edema, and serous detachment at the macula. Moreover, optic neuritis was observed prominently. However, we did not have any clue to identify the exact mechanism of retinal complications and neuroretinitis involvement following chikungunya fever, which is immunologically mediated after chikungunya infections directly or due to the viral infection mediated post fever effect. Recent publication demonstrated that optic neuritis following chikungunya infections has been treated successfully with parenteral steroids [27]. In our case, all patients were treated initially with intravenous methylprednisolone, followed by oral prednisolone for couple of weeks based on the clinical response and resolution of retinal complications.

Recently, studies have demonstrated that sudden low visual acuity syndrome associated to optic disc oedema and macular star exudates is denominated neuroretinitis with symptoms of dengue fever [28,29]. Moreover, retinal hemorrhages are exceedingly rare as a complication of dengue fever and complications specifically occurs toward the end of the febrile period of the infection. On the other hand, central scotoma is the most common ophthalmic complications after dengue fever, however, not all patients with dengue-related maculopathy presented with scotoma. In the case series by Chan et al. [30], demonstrated the patients had central scotoma in association with blurring of vision after febrile period of the dengue infection. In our study patients with dengue fever, the majority of them have macular hemorrhage, macular edema and very few eyes were presented with scotoma, and the results were correlated with the findings of others [31,32]. Recently, studies have demonstrated that retinitis to be the most common ocular manifestation after onset of fever due to pathogenic infections. Some patients had a unilateral large retinitis patch with vascular sheathing and some patients had RAPD with bilateral anterior uveitis, vitritis, multifocal patches of retinitis, macular edema and localized retinal vascular sheathing. In our study, FFA of retinitis was seen as early hypofluorescence with late hyperfluorescence with disc leakage after pathogenic infection like chikungunya and dengue. Moreover, OCT examinations in few eyes showed hyperreflectivity of the nerve fibre layer with after-shadowing in the areas of retinitis associated with fluid-filled spaces in the outer retina and sub foveal serous detachment. Along with few eyes were associated with macular edema and sub foveal detachment in post fever pathogenic infection like chikungunya. In all cases, after systemic steroid medication for 4 to 6 weeks the hyperreflectivity decreased in the areas of retinitis eyes. On the other hand, patients with retinitis following dengue fever were treated with systemic steroids at 1 mg/kg body weight and found to have significant visual benefit.

Typhoid fever is caused by *Salmonella typhi*, leads to enteric fever, septicemia and gastroenteritis. However, Salmonella infections rarely affect the eye either by direct infection or immune-mediated mechanism. An earlier report by Hersing and Duke-Elders [45] demonstrated that typhoid-related uveal complications including iritis, retinal hemorrhage, choroiditis, endophthalmitis and panophthalmitis. Recently, studied have revealed that late-onset endogenous endophthalmitis post typhoid fever resolution [33]. Infections causes typhoid fever is usually affect unilateral or bilateral that may be associated with retinitis and related ocular complications such as Neuroretinitis like picture with optic disc edema and macular hard exudates, macular star, retinal swelling, exudation and edema, vasculitis, haemorrhage, cotton wool spots and retinal and optic nerve head edema [33]. Interestingly, infection of microbial pathogens may be responsible for immune mediated mechanism of ocular and systemic pathology through post-infectious immunological effects. Immune mediated retinitis and its related ocular complications is a clinical diagnosis most often when there is past history of post infection fever days prior to the onset of ocular manifestations. In our study as the disc edema was prominent, and neuroretinitis was considered as the diagnosis, treatment with systemic steroids was initiated due to complications of the retina, especially the macula, which caused decrease in vision. By taking into consideration the time of onset of ocular presentation, previous history of typhoid fever and the response to systemic steroids; the most likely diagnosis was confirmed in post typhoid fever immune mediated retinitis with ocular complications like macular neurosensory detachment and retinitis.

Apart from regular pathogenic induced fever and post-fever retinitis; there is non-infectious mechanisms caused post fever retinal complications. Basically, non-infectious mechanisms causes of retinitis include sarcoidosis, Behcet's disease unilateral or

bilateral. However, the exact mechanism of ocular complications involvement following non-infectious causes of fever is unknown. The possible causes may be direct involvement of delayed immune response after infection. Several characteristics such as delay in onset, partial recovery of disc changes, bilateral involvement in a few patients, and good response to corticosteroid therapy indicate the possibility of an autoimmune mechanism in the pathogenesis of the disease. The onset of visual symptoms a few weeks after fever in our study patients favors the hypothesis that the ocular lesions could be an immune-mediated process rather than a direct pathogenic organism's involvement. The prompt response to steroids also favors an immune-mediated cause.

In summary, although retinal findings following a febrile illness has been very well documented, its morphology varies with the demographic location and aetiological agents. Close association of an internist and ophthalmologist avoids vision threatening complications. Systemic corticosteroids has a major role in neuroretinitis following feverish illness.

ACKNOWLEDGEMENTS

Authors are thanked for skilful technical assistance at Department of Ophtalmology, KIMS, KIIT, Bhubaneswar, India and Vision Care Center for Retina, Bhubaneswar, India.

REFERENCES

1. Prabhushanker M, et al. Bilateral retinitis following typhoid fever. *Int. J. Retina Vitreous*. 2017;3:11.
2. Mine I, et al. Bilateral idiopathic retinal vasculitis following coxsackievirus A4 infection: a case report. *BMC Ophthalmol*. 2017;17:128.
3. Khairallah M, et al. Emergent infectious uveitis. *Middle East Afr. J. Ophthalmol*. 2009;16: 225-238.
4. Vishwanath S, et al. Post-fever retinitis: a single center experience from south India. *Int Ophthalmol* 2014;34:851-857.
5. Shantha JG, et al. Advances in the management of acute retinal necrosis. *Int. Ophthalmol Clin*. 2015;55:1-13.
6. Tam PM, et al. Antiviral selection in the management of acute retinal necrosis. *Clin Ophthalmol*. 2010;4:11-20.
7. Carmichael A. Cytomegalovirus and the eye. *Eye (Lond)*. 26:237-240.
8. Park YS and Byeon SH. Cytomegalovirus retinitis after intravitreal triamcinolone injection in a patient with central retinal vein occlusion. *Korean J. Ophthalmol*. 2008;22:143-144.
9. Rose N, et al. Acute optic neuritis following infection with chikungunya virus in southern rural India. *Int J Infect*. 2011;15:e147-50.
10. Ravi V. Re-emergence of chikungunya virus in India. *Indian J Med Microbiol*. 2006;24:83-84.
11. Ullrich K, et al. Neuroretinitis following bull ant sting. *BMJ Case Rep*. 2012.
12. Sadiq MA, et al. 2015. Endogenous endophthalmitis: diagnosis, management, and prognosis. *J. Ophthalmic Inflamm Infect*. 2015;5:32.
13. Cortez RT, et al. Ocular parasitic diseases: a review on toxocariasis and diffuse unilateral subacute neuroretinitis. *J. Pediatr. Ophthalmol. Strabismus*. 2011;48:204-212.
14. Relhan N, et al. A case of vasculitis, retinitis and macular neurosensory detachment presenting post typhoid fever. *J. Ophthalmic Inflamm Infect*. 2014;4:23.
15. Duke-Elder S and Perkins ES. 1968. *Diseases of the Uveal Tract*. Kimpton, London.
16. Rachitskaya AV, et al. Endogenous endophthalmitis caused by salmonella serotype B in an immunocompetent 12-year-old child. *Arch Ophthalmol*. 2012;130:802-804.
17. Sinha MK, et al. Review of endogenous endophthalmitis caused by Salmonella species including delayed onset Salmonella typhi endophthalmitis. *Semin Ophthalmol*. 2012;27:94-98.
18. Lalitha P, et al. Ocular involvement associated with an epidemic outbreak of chikungunya virus infection. *Am. J. Ophthalmol*. 2007;144:552-556.
19. Mittal A, et al. Optic neuritis associated with chikungunya virus infection in South India. *Arch. Ophthalmol*. 2007;125:1381-1386.
20. Chanana B, et al. 2007. Bilateral macular choroiditis following Chikungunya virus infection. *Eye (Lond)*. 21: 1020-1021.
21. Mahendradas P, et al. 2008. Ocular manifestations associated with chikungunya. *Ophthalmology* 115:287-291.
22. Hood DC, et al. 2009. A comparison of retinal nerve fiber layer (RNFL) thickness obtained with frequency and time domain optical coherence tomography (OCT). *Opt. Express* 17:3997-4003.

23. Aleman TS, et al. 2007. Inner retinal abnormalities in X-linked retinitis pigmentosa with RPGR mutations. *Invest. Ophthalmol. Vis. Sci.* 48:4759-4765.
24. Nakatani Y, et al. 2014. Influences of the inner retinal sublayers and analytical areas in macular scans by spectral-domain OCT on the diagnostic ability of early glaucoma. *Invest. Ophthalmol. Vis. Sci.* 55:7479-7485.
25. Hughes EH and Dick AD. The pathology and pathogenesis of retinal vasculitis. *Neuropathol. Appl Neurobiol.* 2009;29:325-340.
26. Balansard B, et al. Necrotising retinopathies simulating acute retinal necrosis syndrome. *Br. J. Ophthalmol.* 2005;89:96-101.
27. Mahesh G, et al. A case of bilateral presumed chikungunya neuroretinitis. *Indian J Ophthalmol.* 2009;57:148-150.
28. Bhatti MT, et al. Macular star in neuroretinitis. *Arch. Neurol.* 2006;58:1008-1009.
29. Yang CM, et al. Irrigation-free vitreoretinal surgery for recurrent retinal detachment in silicone oil-filled eyes. *Eye.* 2006;20:1379-1382.
30. Chan DP, et al. Eye Institute Dengue-Related Ophthalmic Complications Workgroup. 2006. Ophthalmic complications of dengue. *Emerg. Infect. Dis.* 12:285-289.
31. Teoh SC, et al. Eye Institute Dengue-Related Ophthalmic Complications Workgroup. Ophthalmic complications of dengue. 2006. A Re-look at Ocular Complications in Dengue Fever and Dengue Haemorrhagic Fever. *Dengue Bulletin* 2006;30:184-190.
32. Teoh SC, et al. Optical coherence tomography patterns as predictors of visual outcome in dengue-related maculopathy. *Retina.* 2010;30:390-398.
33. Shah AM, et al. Viral retinitis after intravitreal triamcinolone injection in patients with predisposing medical comorbidities. *Am. J. Ophthalmol.* 2010;149:433-440.e1.