

# A Rare Primary Synovial Sarcoma of Lung - Case Report with Literature Review

Arun RD\*

AIIMS Nursing, Sijua, Patrapada Bhubaneswar, India

## Case Report

Received date: 12/12/2016

Accepted date: 01/05/2017

Published date: 01/12/2017

### \*For Correspondence

Arun RD, Nursing Officer, AIIMS Nursing Sijua, Patrapada Bhubaneswar, India 751019, Tel: 91 9658558548.

**E-mail:** rd.arunn@gmail.com

**Keywords:** Tumor, Patient, Primary synovial sarcoma.

### ABSTRACT

Primary synovial sarcoma of lung is an extremely rare tumor. The etiology and pathogenesis of sarcomas lung are not well understood. A definitive diagnosis requires detailed radiological imaging, immunohistochemical staining and molecular genetics techniques. Histologically it was classified in to monophasic and biphasic synovial sarcoma. We reported a case of primary synovial sarcoma of lung presenting with hoarseness of voice, left side chest pain, cough and fever. Contrast enhanced computer tomography revealed a large homogeneous mass, occupying most of the left hemi thorax. Ultrasound (US) guided fine needle aspiration cytology (FNAC) of lung revealed synovial sarcoma-monophasic type. Immunohistochemistry (IHC) analysis revealed positive for bcl-2 and CD-99. Hence it was a complete left lung obstruction with Eastern Cooperative Oncology Group (ECOG) score of 3. Eventhough Surgical management is the primary option, due to high risk and poor performance score we have planned for 3 cycles of chemotherapy (Ifosphamide plus Adriamycin). Treatment response shows no response and progressive disease and furtherely trearted with supportive care.

## INTRODUCTION

Synovial sarcoma is commonly seen in young adults. Most of the cases occur in upper and lower extremities and less commonly seen in head and neck and less than 10% accounts intra thoracic sites including lungs, mediastinum etc. This tumor is classified morphologically biphasic and monophasic among which biphasic is common and monophasic is uncommon<sup>[1]</sup>. Primary synovial sarcoma of lung is very rare with prevalence of 0.1% to 0.5% of all type of lung malignancies. Here, we reported a case of synovial sarcoma of left lung in a 37 year old male<sup>[2]</sup>.

## CASE REPORT

A case of 37 years old gentlemen come with the history of hoarseness of voice, left side chest pain, cough with scanty expectoration for past 2 months, low grade fever with chills and rigor for past one month. The patient had history of smoking and alcohol intake over long time. There was no history of exposure to asbestos, arsenic or radon exposures.

Vital parameters recorded as blood pressure 120/80 mm Hg; pulse, 96 beats/min; respiratory rate, 29 breaths/min; and temperature 98.6°C; spO<sub>2</sub> at 92%, ECOG score as 3. Examination to respiratory system revealed decreased movement of the left side of the chest wall with ipsilateral fullness. Trachea was shifted to right. Vocal fremitus was diminished and percussion note was dull over all areas of left side. Vesicular breath sound was diminished and vocal resonance was decreased on the left side. Examination of abdomen did not reveal any lymphadenopathy, ascites, and hepatosplenomegaly. Cardiovascular system shows mild right ventricular hypertrophy. All other systemic examination ruled out no abnormality. Chest x-ray demonstrated opacity occupying almost whole of the left hemithorax. Ultrasound (US) guided fine needle aspiration cytology (FNAC) was obtained from left lung mass showing features of malignant spindle cell neoplasm. No cellular elements seen from cytology report obtained from bronchial wash. Sputum smear shows negative for malignant cells. US guided lung biopsy was performed and the histopathological examination revealed features of monophasic synovial sarcoma. Immunohistochemistry (IHC) showed tumor cells were positive

for Bcl-2 and CD-99 positive and negative for CD-34 AND CK-7. Contrast enhanced computer tomography (CECT) showed a large mass of size 20 × 14 cm involving almost whole of the left lung compressing main pulmonary artery, oesophagus and main bronchus with partial collapse of left upper lobe. Minimal left pleural effusion was present. No significant lymphadenopathy was seen. Cardiothoracic vascular surgery evaluation done and discussed with complete team. Eventhough Surgery is the primary option and it was not planned because of high risk and patient refusal. The patient was planned for neoadjuvent chemotherapy with 3 cycles of Ifosphamide (2 mg/m<sup>2</sup> day 1 to day 4) plus Adriamycin (65mg/m<sup>2</sup> day 1) in 21 days inteval. After completion of neoadjuvent chemotherapy plain CT scan revealed no response and progressive disease and case referred for surgical management. But due to poor performance of patient ECOG Score of 4 considered as high risk and switched treatment to palliative and supportive care. Then patient treated with opoid analgesics, nebulisation, oxygen trtherapy, systemic steroids. At last, over 1 year of treatment we lost the patient with cardio respiratory failure due to pulmonary hemorrhage and overall decline in patient performance.

### DISCUSSION

Synovial sarcoma most commonly occurs in the extremities of young and middle aged adults, typically in the vicinity of large joints. It may arise in unusual locations [3].

Primary pulmonary sarcomas are very rare and comprise only 0.5% of all primary lung malignancies with only a few cases reports in the literature [4]. Primary pulmonary and mediastinal synovial sarcomas are more aggressive than soft tissue synovial sarcomas with rare distant metastasis [3].

It has a slight male predilection, and is not related to cigarette smoking. The diagnosis of primary pulmonary synovial sarcoma requires a combination of clinical, radiological, pathological and immunohistochemical investigations to exclude alternative primary tumours and metastatic sarcoma [2].

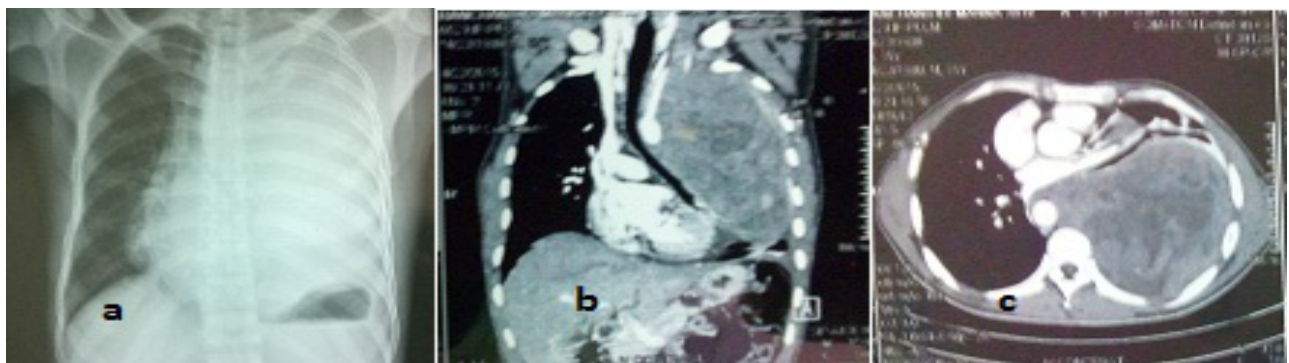
Sarcomas are a heterogeneous group of malignant mesenchymal tumors of difficult classification. Primary pulmonary synovial sarcomas are of four subtypes – monophasic fibrous (spindle), monophasic epithelial, biphasic, and poorly differentiated, monophasic subtype being most common [5,6].

History collection, physical examination and Radiographic studies includes chest x ray, CT scan helps in diagnosis. Immunohistochemistry plays a crucial role in the diagnosis of Synovial sarcoma. Diagnosis of biphasic subtype is easy as both, epithelial and spindle cell components are present. Hence, to differentiate monophasic subtype of synovial cell sarcoma from others, immunohistochemistry is essential [5]. Most monophasic type synovial sarcomas show immunoreactivity for cytokeratins and epithelial membrane antigen (EMA). Furthermore, 30% of them are protein S-100 positive, 60–70% CD 99 positive and 75–100% Bcl-2 positive [7]. There is considerable variability in both histological appearance and responsiveness to therapy. Synovial sarcoma has a consistent chromosomal translocation t(x:18) (p11;q11) and this translocation fuses SYT gene with either of the two homologous genes SSSX1 OR SSX2 [7].

Sixty six percent of primary pulmonary synovial sarcoma is centrally located and present with obstructive pneumonia, hemoptysis, dyspnea, cough and fever [8].

There is no standardized therapy; most patients are treated with surgery or surgery with adjuvant radiation therapy. Surgical management is the primary option followed by adjuvant chemotherapy and radiation therapy. There are limited controlled studies regarding chemotherapy because of rarity of this tumor. The present case was planned for chemotherapy as an initial treatment.

Doxorubicin and ifosfamide are the two drugs used either in monotherapy or combination with the best established response rates in adult soft tissue sarcomas. Synovial sarcoma is chemosensitive to ifosfamide and doxorubicin, with an overall response rate of approximately 24% [9]. The present case received palliative chemotherapy with ifosfamide and doxorubicin combination regimen (**Figure 1**).



**Figure 1.** Chest x ray and CECT thorax showing a large space occupying lesion with complete left lung obstruction.

There is evidence of efficacy of new drugs such as taxanes; with regard to target therapy pazopanib seems especially active in leiomyosarcomas and synovial sarcomas [10]. Gefitinib monotherapy in advanced Synovial sarcoma refractory to conventional

chemotherapy doxorubicin and ifosfamide <sup>[11]</sup>. Oral vascular endothelial growth factor receptor (VEGFR) inhibitors such as sunitinib, sorafenib and cediranib have shown disease stabilization in patients with advanced synovial sarcoma. Forty-nine percent of patients with synovial sarcoma on the phase II trial of pazopanib had no evidence of disease progression at 12 weeks <sup>[12]</sup>. Newer approaches include CXCR4 inhibition, immune-based therapies (NY-ESO-1), targeting epigenetic misregulation with HDAC inhibitors and targeting developmental pathways such Notch and Hedgehog <sup>[13]</sup>. The overall prognosis is poor in primary synovial sarcoma with a 5 year survival rate of approximately 50%. Tumor size >9 cm, male patients, over the age of 20 years, extensive tumor necrosis, high grade, large number of mitosis and neurovascular invasion have poor prognosis.

### SUMMARY

There is no standard protocol for treating pulmonary synovial sarcoma. We treated a case of biphasic synovial sarcoma with chemotherapy of 3 cycles of doxorubicin and ifosfamide and the post evaluation CT scan shows that no response for chemotherapy and finally we referred the case for palliative management. But, due to paucity of data in literature, there is no standard guidelines in the field of expertise regarding management of primary synovial sarcoma of lung, also its long-term prognosis and needs further evaluation.

### REFERENCES

1. Devita, et al. Principles and practice of oncology, Lippincott Williams & Wilkins. 2008;1744-1757.
2. Alcaraz-García P, et al. Primary pulmonary biphasic synovial sarcoma: A case report and literature review. Centre for Interdisciplinary Research. 2012;80:67-71.
3. Kang MK, et al. Primary synovial sarcoma of the parietal pleura: A case report. Korean J Thorac Cardiovasc Surg. 2013;46:159-161.
4. Yaseen SB, et al. Primary pulmonary synovial sarcoma: Diagnosis on squash smears. J Cytol. 2015;32:56-58.
5. Roy PP, et al. Primary synovial sarcoma of lung. Am J Med. 2012;4: 241-243.
6. Trassard M, et al. Prognostic factors in localized primary synovial sarcoma: A multicenter study of 128 adult patients. J Clin Oncol. 2001;19:525-34.
7. Charalampos M, et al. Primary monophasic synovial sarcoma presenting as a pulmonary mass: A case report. J Med Case Reports. 2008;2:18.
8. Cabuk D and Ustuner B. Primary synovial sarcoma of lung. Korean J Thorac Cardiovasc Surg. 2014;47:306-309.
9. Devleena, et al. Primary synovial sarcoma of lung. Lung India. 2014;31: 277-279.
10. Papai Z. Medical treatment of soft tissue sarcomas based on the histological subtype. Magy Onkol. 2014;58:53-58.
11. Ray-Coquard I and Le Cesne A. A phase II study of gefitinib for patients with advanced HER-1expressing synovial sarcoma refractory to doxorubicin-containing regimens. Oncologist. 2008;13:467-473.
12. Doroshow JH, et al. Antiangiogenic approaches for the treatment of advanced synovial sarcomas. Curr Opin Oncol. 2012;24:425-430.
13. Palmerini E, et al. Emerging therapeutic targets for synovial sarcoma. Expert Review Anti-cancer Therapy. 2014;14:791-806.