



ACCESSORY LIVER A RARE FINDING: A CADAVERIC STUDY

¹Sidharth Sankar Maharana* and ²Anuj Sharma

¹Demonstrator, Department of Anatomy, Maharishi Markandeshwar Medical College and Hospital, Kumarhatti, Solan (Himachal Pradesh)

²Associate Professor, Department of Pathology, Maharishi Markandeshwar Medical College and Hospital, Kumarhatti, Solan (Himachal Pradesh)

*Corresponding author, E-mail: siddharth.maharana@gmail.com

ABSTRACT: The Accessory Liver is rarely found in the human body. If present it was usually asymptomatic and found incidentally at laparotomy or autopsy. Its misidentification as a pathologic mass led to surgery. In the present study the accessory liver was found while doing routine dissection of the abdomen. In the present study 21 human cadavers were dissected which were embalmed with 10% formalin and fixed. The purpose of study was to highlight the presence of accessory liver in the body and importance in the human body and to compare the study with studies done by other authors. This study gave ideas to the surgeons and physicians in their diagnosis and treatment.

Key words: Liver, Accessory lobe, Variation, Hepatic lobes

INTRODUCTION

Liver is the largest wedge-shaped gland of the body. It lies below the right dome of the diaphragm and occupies the right hypochondric, right lumbar and epigastric regions. It is divided into anatomical right and left lobes by the line of attachment of falciform ligament, fissure for ligamentum venosum and fissure for ligamentum teres. The porta hepatis is situated on its inferior surface and transmits the blood vessels, nerves and lymphatics of the liver [1]. Gross abnormalities of the liver were rare in spite of its complex development [2]. The common gross abnormalities were irregularities in form, in the number of lobules and in the presence of cysts. A rare common abnormality was the occurrence of one or more accessory livers or lobes. Accessory lobes were seen in numerous places. These accessory lobes might be attached to the liver by a mesentery or by its parenchyma. If attached by a mesentery it must contain hepatic artery, hepatic vein, portal vein and a bile duct. Accessory lobe in some cases found in the vicinity of gallbladder or fossa or solitary lobe connected with liver by pedicle or mesentery containing vascular supply and arises from superior surface [3]. In most of literatures accessory lobe was found in the suspensory ligament [4, 5, 6]. Embryologically liver and lungs were developed from endodermal diverticulum of foregut and are in close proximity. Collan et al. [7] concluded that the liver tissue in the vicinity of the liver with no connection was termed ectopic liver lobe while the liver tissue in connection with main liver was termed as an accessory lobe [7]. The mechanism of presence of the accessory lobe of liver is still controversial. These congenital anomalies could cause diagnostic confusion for physicians, radiologists, surgeons and anatomist during procedures like biopsy, transplantation and lobectomies.

MATERIAL AND METHOD

This study was conducted in the Department of Anatomy of Maharishi Markandeshwar Medical College, Kumarhatti and District: Solan (Himachal Pradesh). 21 preembalmed cadavers were taken for the study. The livers were carefully studied for the presence of Accessory lobes. The site and size of the tissue was recorded and photographed. Histological examination of tissue was done to confirm the nature of tissue. The present study will be compared with the studies done by other authors.

RESULTS

During routine cadaveric dissection classes for undergraduate medical students in the anatomy department of Maharishi Markandeswar Medical college, Kumarhatti, and District: Solan. We found Accessory lobe of liver lobe in 1 case 4.76% (figure-1). A small oval lobe of liver in an adult male cadaver which was approx. 70 years. It was located posterior to the left of the porta hepatis and to the left of the caudate lobe separated from it by a well defined fissure. Its size was 34mm × 18mm. This lobe is visible as a prominence on the inferior and posterior surfaces to the right of the groove formed by the ligamentum venosum. It lied posterior to the left to the porta hepatis. The attachment of falciform ligament and position of gall bladder were found normal. (Figure-1 and 2).

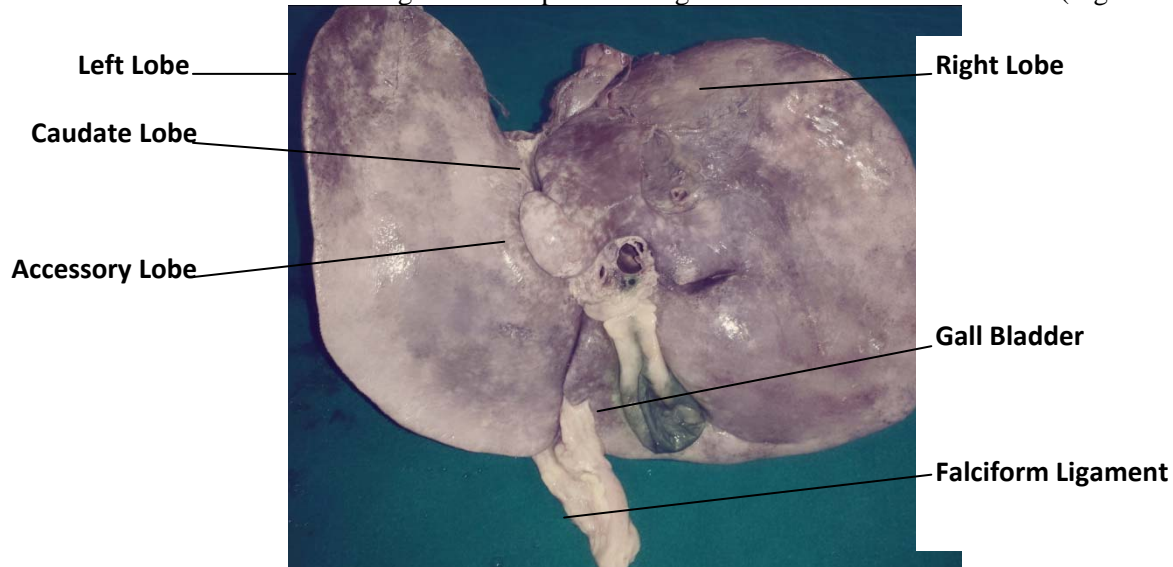


Figure-1: Liver structure

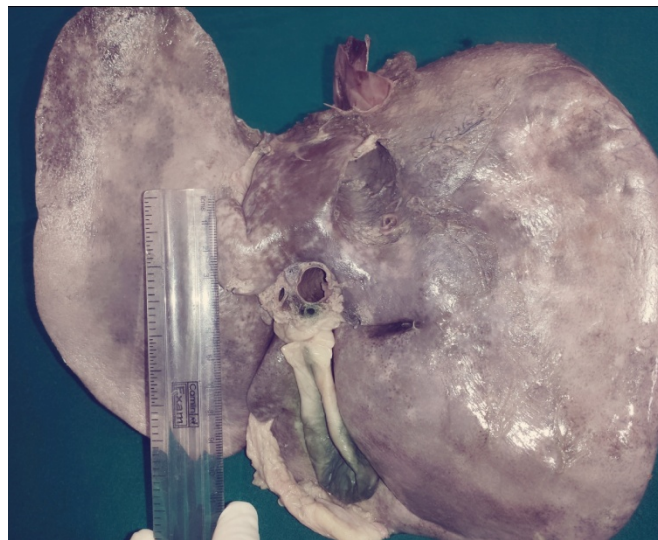


Figure-2: Accessory liver

Histopathology of Accessory lobe

In the histological examination it was found that the tissue in slide was identical to the liver. It was not having any pathological finding. It was having clear liver parenchyma. (Figure-3)

In the present study the accessory lobe found in 4.76% of cases which was attached to the main liver, it was histologically confirmed that the lobe was accessory liver because tissue present in the lobe resembled with the histological picture of liver.

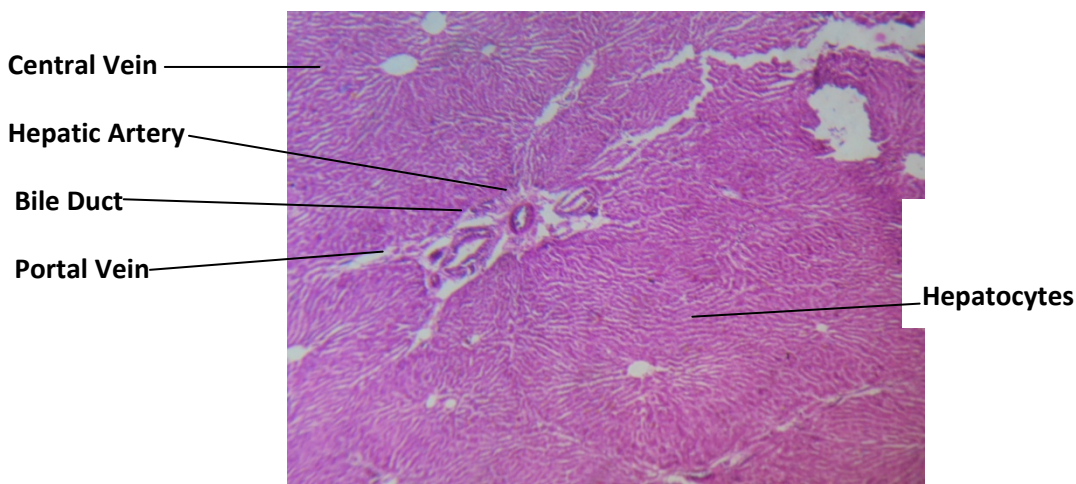


Figure-3: Histological Structure of Tissue

DISCUSSION

Riedel (1888) was first to report that the occasional tongue like projection of right lobe of liver extending to or below the umbilicus [8]. Caygill and Gatenby [9] in their study reported that there were four types of abnormally positioned livers (1) a liver with unconnected the main liver and is attached to the gallbladder or the intra-abdominal ligaments; (2) a microscopic ectopic liver found in the wall of the gallbladder; (3) a large accessory liver which is connected to the main liver by a stalk, and (4) a small accessory liver lobe (10-30g in weight) which was attached to the main liver[9].

Accessory lobe of the liver was a rare congenital anomaly found incidentally at autopsy or laparotomy. They commonly found on the undersurface of the liver and have also seen on the gallbladder surface, hepatogastric ligament near umbilicus, adrenal gland, pancreas and the thoracic cavity [10].

Sato et al. [11] in a series of 1800 laproscopies described that the accessory lobe was a congenital anomaly found in approximately 19% of cases with the incidence of ectopic liver lobe and accessory liver lobe being 0.7% [11]. In the present study it is found in 4.76% of cases only, where as Muktyaz et al. [12] 14.6% of cases reported by them [12].

CONCLUSION

Accessory lobe of liver is the rare finding which may not produce any sign or symptom. But sometimes the mass is considered as a tumor. Knowledge of variations of liver may be important to physicians before planning surgery involving liver and for avoiding diagnostic misinterpretation of other disease.

REFERENCES

- [1] Standerling S, Ellis H, Healy JC. Live. In: standering S,eds.Gray's Anatomy: The Anatomical Basis of clinical practice. 39th ed. London: Elsevier Churchill Livingstone; 1213-1225.
- [2] Aktan Z.A, Savas R, Pinar Y and Arslan O. 2001. Lobe and segment anomalies of the liver. Journal of the Anatomical society of India, vol.50, no.1, pp.15-16
- [3] Friedman P.S, Solis L-Cohen and Levine L. 1947.Accessory lobe of liver and its significance in roentgen diagnosis, American journal of Roentgenology vol.57,pp.601-603
- [4] Guber, Wenger.1987.Beobachtungen aus der Menschlichen and Vergluchenden Anatomic. Berlin.part 1,p.48
- [5] Kolb.1868. Wein Med.Wchnschr; pp.1357-1404

- [6] Tarozzi.G. 1904. Osservazioni e Ricerche Sopra Le Inclusioni epatiche nel Legamento Triangolare sinistro del fegate sperimentale. Arch. diBiol, 58:499
- [7] Collan Y, Hakkiluoto A, Hastbacka J. Ectopic Liver. Ann CHir. Gynaecol 1978; 67:27-29
- [8] Riedel BMKL.1888. Uber den Zungenformigen Fortsatz des rechten Leberlappens and Seine pathognostiche Bedeutung fur die Erkrankung der Gallenblase nebst Bemerkungen uber Gallensteinoperationen. Berlin Klin Wschr 25:577
- [9] Caygill CP, Gatenby PA. 2004. Ectopic Liver and hepatocarcinogenesis. Eur J Gastroenterol Hepatol;16 (8):727-9
- [10] Anand S S, Chauhan M S. 2002. Intrathoracic Accessory Lobe of liver.Indian J Nuclear Med;17(1):44-5
- [11] Sato S, Watanabe M, Nagasawa S, Niigaki M, Sakai, Akagi S. 1998. Laproscopic observations of congenital anomalies of the liver. Gastrointest Endosc, 47:136-140
- [12] Mukytaz H, Nema U, Rakesh G and A.K.Sharma. 2013. Morphological variations of liver lobes and its clinical significance in north Indian population. Global Journal of Medicine & Medical Sciences., vol(1):1-5

International Journal of Plant, Animal and Environmental Sciences

