

CBCT Analysis of Root Canal Filling Using Different Obturation Techniques (*In Vitro* Study)

Amjad Saud Alsharif^{1*} and Samla Mohamed El Sherief²

¹6th year Dental Student at College of Dentistry, Umm Al-Qura University, Saudi Arabia

²Assistant Professor in Department of Endodontics, Faculty of Dentistry, Umm Al-Qura University, Saudi Arabia

Research Article

Received date: 01/01/2019;

Accepted date: 10/05/2019;

Published date: 17/05/2019

***For Correspondence:**

Amjad Saud Alsharif, Dental Student at College of Dentistry, Umm Al-Qura University, Saudi Arabia

Keywords: Obturation, Rotary system, Cone beam, Gutta-percha, Calamus

ABSTRACT

Introduction: The function of root canal filling is to prevent the reinfection and to hermetic seal the root canal space. Many root canal filling techniques have developed to accomplish three-dimensional obturation of root canal system.

The Aim of the study: To evaluate the quality of the root canal filling using three different obturation techniques with CBCT.

Materials and methods: Thirty extracted human single rooted teeth were prepared for access cavity and working length determining, cleaning and shaping was done using ProTaper Next rotary system. Teeth randomly divided into three groups (n=10) according to the obturation techniques. The first group received root canal filling by lateral compaction technique. The second group received root canal filling by using single cone technique (ProTaper F3). The third group received root canal filling by using Calamus with gutta-percha cartridges. The resin-based sealer that used is the same for all groups.

Results: CBCT cross section evaluated at three levels (apical, middle, coronal). The result showed that with lateral compaction and single cone technique voids present more at the middle and coronal third. With Calamus technique more voids at the coronal part. The comparison of the obturation techniques showed no significant differences between the three groups.

Conclusion: from our result we can conclude that all the systems showed minimum voids at the apical part rather than the middle and coronal part. There was no significant difference between obturation techniques. There wasn't any system showed obturation void-free.

INTRODUCTION

Root canal obturation is a procedure that fills the root canal space with inert filling materials at the final stage of root canal treatment, after cleaning and shaping. The filling should be well adapted to the canal walls to achieve long-term stability, and the canal should be densely compacted with a homogeneous mass of gutta-percha [1,2]. A solid core cemented in the root canal with a sealer is the most use obturation methods [3]. Many root canal filling techniques developed in the hope of achieving total root canal obturation [4].

Lateral compaction of gutta-percha is the gold standard technique [5]. Single cone was introduced to provide the gutta-percha/root canal sealer balance. Warm gutta-percha filling is the standard material used to provide an apical seal, and injection of warm gutta-percha to fill the coronal two thirds of the root canal. This method has an advantage of a continuous filling [6].

Endodontic sealer is used in combination with gutta-percha due to lack of adhesion from gutta-percha. Adaptability of a sealer to the dentin is the primary factor influencing microleakage and reinfection of the root canal [7].

Rotary nickel-titanium (NiTi) instruments used for root canal instrumentation. The root canal preparations with NiTi rotary systems are more conical than manual preparations. Tapered single cones introduced in the market to improve the gutta-percha/root canal sealer balance [6,8]. Prepared the root canal with ProTaper Next files which exhibit a rectangular cross-section design for superior strength that improves the file's canal shaping effectiveness. They are manufactured by NiTi to provide flexibility and enhance the cyclic fatigue resistance for files [9].

The advent of computed tomography (CT) has started a revolution of information in health studies and has contributed to the planning, diagnosis, treatment, and prognosis analysis of several diseases. Cone-beam computed tomography (CBCT) is a recently developed technology with potential for applications in different areas of research and clinical dentistry [10]. It designed for imaging hard tissues of the maxillofacial region, and capable of providing a 3-dimensional representation of the maxillofacial skeleton including the teeth and their supporting tissue with minimal distortion [8,11].

MATERIALS AND METHODS

Specimen Selection

A total of thirty extracted human premolars teeth used after obtaining approval from the Institutional Reviewing Board at UQUdent (UQUdent-IRB). The selected teeth with single canal and fully formed root apex. Teeth with multi-canal or calcification or fractures or severe curvature excluded from the study sample.

Specimen Preparation

The samples were cleaned from any debris then stored first with 10% of sodium hypochlorite for one day and then stored in saline. Teeth then decoronated with a diamond wheel and achieve working length about 16 mm using K-type file number 10 inserted into the canal until it visible from the apical foramen, working length set 1 mm short of the length (DentsplyMaillefer, Ballaigues, Switzerland). Teeth were divided randomly into three group (n=10) and mounted in transparent acrylic resin.

Preparation and Obturation Techniques

The sample was instrumented start with K-type file number 15 to establish apical patency and followed with K-type file number 20 and 25 (DentsplyMaillefer, Ballaigues, Switzerland). Irrigation was done using 2 ml of 2.5% sodium hypochlorite between each file The root canal then instrumented using ProTaper Next rotary system according to the manufacturers' instructions (DentsplyMaillefer, Ballaigues, Switzerland), three files used X1-yellow, X2-red and X3-blue. Each file coated with Glyde (Dentsply Maillefer). Irrigation with 2 ml of 2.5% sodium hypochlorite between each file during instrumentation followed by 17% of EDTA aqueous solution. EDTA 17% used for the final rinse (MetaBiomed, Korea). Dryness was with the paper point. According to the groups we have three obturation techniques (Lateral compaction technique, Single cone technique, Calamus technique).

Lateral Compaction Technique

The first group received root canal filling by lateral compaction technique. F3 ProTaper master gutta-percha cone (Sure-endo, Bourg La Reine, France) coated with epoxy resin-based sealer and inserted to the full working length, some of accessory gutta-percha cone coated with the same sealer and inserted into the canal. Lateral compaction performed until the canal filled and spreader couldn't introduce more than cementodentinal junction.

Single Cone Technique

The second group received root canal filling by using single cone technique. F3 ProTaper gutta-percha cone selected (DentsplyMaillefer, Ballaigues, Switzerland) and coated with epoxy resin-based sealer and inserted to the full working length.

Calamus Technique

The third group received root canal filling by using Calamus with gutta-percha cartridges (DentsplyMaillefer, Ballaigues, Switzerland). F3 ProTaper master gutta-percha cone inserted to the canal and coated with epoxy resin-based sealer to the full working length, pack the filling material and place within 5 mm to the canal terminus, then flow the gutta-percha material into the canal and compact the canal with plugger until the desired level.

Imaging of Samples

All the three group scanned by cone-beam computed tomography (i-CAT); three horizontal section analysed (apical third, middle third and coronal third) with an exposure time of 26.9 seconds, at 120 kvp and 37.07 mAs.

Statistical Analysis

The data was statistically analyzed using one-way ANOVA test with Tukey’ s honestly significant difference (HDS). The significance level was 0.05, using Statistical Package for Social Science (SPSS) Version 22 for mac.

RESULTS

CBCT cross section evaluated at three levels (apical, middle, coronal). We found with lateral compaction technique voids present more at the middle and coronal third. Also the same with single cone technique. The percentage of voids with Calamus technique are lesser in the middle and coronal third (Table 1, Figures 1 and 2). The result showed no significant differences between the three groups (p-value=0.418), as shown in Table 2.

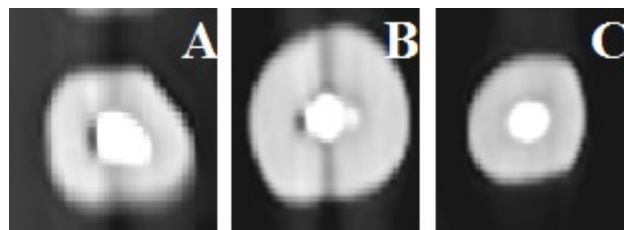


Figure 1. Different obturation technique and voids. A: Presence of voids (>0.5 mm <1 mm), Lateral compaction technique. B: Presence of small voids (<0.5 mm) Single cone technique, Coronal third. C: Gutta-percha adapted to the canal wall Calamus technique.

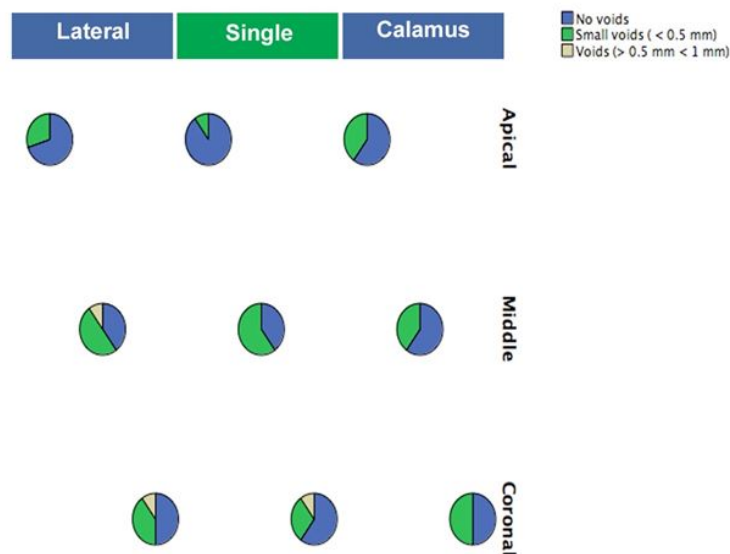


Figure 2. Comparison between the technique used and the presence of voids in each level.

Table 1. Comparison between the technique used and the presence of voids in each level.

	Lateral			Single			Calamus	
	No voids	Small voids (< 0.5 mm)	Voids (> 0.5 mm, < 1 mm)	No voids	Small voids (< 0.5 mm)	Voids (> 0.5 mm <1 mm)	No voids	Small voids (< 0.5 mm)
Apical	70%	30%	0%	90%	10%	0%	60%	40%

Middle	40%	50%	10%	40%	60%	0%	60%	40%
Coronal	50%	40%	10%	60%	30%	10%	50%	50%
Chi (P-value)	0.286			0.084			0.657	

Table 2. Comparison between the techniques used.

	N	Mean	SD	F (P-value)
lateral (apical)	10	0.3	0.483046	1.033 (0.4183)
Lateral (middle)	10	0.7	0.674949	
Lateral (coronal)	10	0.6	0.699206	
Single (apical)	10	0.1	0.316228	
Single (middle)	10	0.6	0.516398	
Single (coronal)	10	0.5	0.707107	
Calamus (apical)	10	0.4	0.516398	
Calamus (middle)	10	0.4	0.516398	
Calamus (coronal)	10	0.5	0.527046	
Total	90	0.455556	0.564116	

N: Number of the Sample; SD: Standard Deviation.

DISCUSSION

Root canal filling should seal three-dimensional the root canal to prevent the penetration of bacteria and their product [5]. Different type of obturating systems can influence the quality of obturation [12]. The presence of voids within the root canal filling may be affected by anatomical configuration, canal preparation quality, sealer volume, the expertise of the operator's and obturation techniques [13]. Evaluation of the quality of root canal in the long oval canal may be compromised [14]. It is not easy to achieve a complete filling due to dimensional changes and lack of adhesion from gutta-percha, which is a reason to use an endodontic sealer. The adaptability of a sealer to the dentin is an important factor influencing microleakage and reinfection [15].

The quality of obturation system then assessed by using cone-beam computed tomography. Cone-beam computed tomography is designed for imaging hard tissue. It provides clear images of highly contrasted structures [11].

The human extracted teeth used in this study were straight with a single canal that can be easily prepared and standardized. Prepared the root canal with ProTaper Next file which has been introduced that have rectangular design and progressive and regressive percentage tapers on a single file [16].

In the present study, three technique used lateral compaction which is the most popular obturation technique. Single cone obturation technique has popularized through using one cone match to the tapering of the rotary system file. Calamus which is a warm vertical compaction and provide better filled to the canal and excellent seal. The same operator did all the procedures to eliminate inter-operator variability.

Evaluation of teeth using cone-beam computed tomography at three levels apical, middle and coronal to identify the presence of the voids and to categorise the size of the voids according to these criteria (gutta-percha or sealer is well adapted to the canal wall, Presence of small voids (<0.5 mm), Presence of voids (>0.5 mm <1 mm)). More voids were seen in coronal as compared to the middle and apical third, this was in agreement with Mustafa [17], Gupta et al. [5]. There is no significant difference between the obturation techniques and no filling technique produced void-free root canal fillings, this was in agreement with Kqiku et al. [18], Peng et al. [19], Tasdemir et al. [20] Dadresanfar et al. [21] Samson et al. [22], Keles et al. [13] and disagreement with Yilmaz result which showed significant difference between the different obturation techniques. Guigand result showed thermafil has no gaps unlike lateral compaction which disagrees with the present study [23,24].

CONCLUSION

Under the limitation of this *in vitro* study, we can conclude the following; all the three techniques (lateral condensation, single cone and Calamus) showed minimum voids at the apical part rather than the middle and coronal part. The obturation techniques showed no significant difference. No obturation technique can produce void-free root canal filling.

RECOMMENDATION

Further larger sample size will be needed. To provide different type of sealer used with different obturation techniques. Further research is recommended to be applied *in-vivo*.

ACKNOWLEDGMENT

I would like to thank my advisor Dr. Samia Elsherief for her remarkable efforts and patience and Dr. Hind Latif for her support. I would thank Dr. Rabab Dosoky for her assistance in the statistical analysis of this study. I also appreciate Mr. Reda kamel for his assistant in the capture of the images. Finally, thank my college Faculty of Dentistry of Umm Al-Qura University.

REFERENCES

1. Kim S, et al. Comparison of the percentage of voids in the canal filling of a calcium silicate-based sealer and gutta percha cones using two obturation techniques. *Materials*. 2017;10:1170.
2. Wolf M, et al. 3D analyses of interface voids in root canals filled with different sealer materials in combination with warm gutta-percha technique. *Clin Oral Invest*. 2014;18:155-161.
3. Gencoglu N, et al. Comparison of different gutta-percha root filling techniques: thermafil, quick-fill, system b, and lateral condensation. *Oral Surg Oral Med Oral Pathol Oral Radiol Endod*. 2002;93:333-336.
4. Schilder H. Filling root canal in three dimensions. *J Endod*. 2006;32:281-290.
5. Gupta R, et al. Comparative evaluation of three different obturating techniques lateral compaction, thermafil and calamus for filling area and voids using cone beam computed tomography: An invitro study. *J Clinical Diagnostic Res*. 2015;9:ZC15-ZC17.
6. Robberecht L, et al. Qualitative evaluation of two endodontic obturation techniques: tapered single-cone method versus warm vertical condensation and injection system An in vitro study. *J Oral Sci*. 2012;54:99-104.
7. Schafer E, et al. Percentage of gutta-percha - filled areas in canals instrumented with nickel-titanium systems and obturated with matching single cones. *J Endod*. 2013;39:924-928.
8. Abella F, et al. Endodontic applications of cone beam computed tomography: case series and literature review. *J Italiano di Endodonzia*. 2015;29:38-50.
9. Elnaghy A and Elsaka S. Evaluation of root canal transportation, centering ratio, and remaining dentin thickness associated with protaper next instruments with and without glide path. *J Endod*. 2014;40:2053-2056.
10. Decurcio D, et al. Effect of root canal filling materials on dimensions of cone-beam computed tomography images. *J Appl Oral Sci*. 2012;20:260-267.
11. Scarfe W, et al. Clinical applications of cone-beam computed tomography in dental practice. *J Can Dent Assoc*. 2006;72:75-80.
12. Dhingra A, et al. Comparative evaluation of the canal curvature modifications after instrumentation with one shape rotary and wave one reciprocating files. *J Conserv*. 2014;17:138-141.
13. Keles A, et al. 3D Micro-CT evaluation of root filling quality in oval-shaped canal. *Int Endod J*. 2014;47:1177-1184.
14. Sluis L, et al. An evaluation of the quality of root fillings in mandibular incisors and maxillary and mandibular canines using different methodologies. *J Dent*. 2005;33:683-688.
15. Huang Y, et al. Evaluation of the sealing ability of different root canal sealers: a combined SEM and micro-CT study. *J Appl Oral Sci*. 2018;26:e20160584.
16. Capar I, et al. Effects of ProTaper Universal, ProTaper Next, and HyFlex instruments on crack formation in dentin. *J Endod*. 2014;40:1482-1484.
17. Mustafa A. Evaluation of density and homogeneity of three different root canal obturation techniques: a three-dimensional computed tomography In Vitro study. *Tikrit J Dent Sci*. 2013;17-23.

18. Kqiku L, et al. A comparative study of five different obturation techniques. *Acta Stomatol Croat.* 2006;40:3-11.
19. Peng L, et al. Outcome of root canal obturation by warm gutta-percha versus cold lateral condensation: a meta-analysis. *J Endod.* 2007;33:106-109.
20. Tasdemir T, et al. Evaluation of apical filling after root canal filling by 2 different techniques. *J Can Dent Assoc.* 2009;75:201
21. Dadresanfar B, et al. Comparative study of the sealing ability of the lateral condensation technique and the BeeFill system after canal preparation by the Mtwo NiTi rotary system. *J Oral Sci.* 2010;52:281-285.
22. Samson E, et al. An in-vitro evaluation and comparison of apical sealing ability of three different obturation technique-lateral condensation, obtura II, and Thermafil. *J Int Oral Health.* 2013;5:35-43.
23. Guigand M, et al. Comparative study of two canal obturation techniques by image analysis and EDS microanalysis. *British Dent J.* 2005;198:707-711.
24. Yilmaz A and Karagoz-Kucukay I. In Vitro comparison of gutta-percha-filled area percentages in root canals instrumented and obturated with different techniques. *J Istanbul Univ Fac Dent.* 2017;51:37-42.