

Management of Corneal Ulcer

N P Singh¹, S K Jhirwal^{2*}, T K Gahlot²

¹VO, Rural Polyclinic, Hingonia, Jaipur, Rajasthan, India.

²Department of Veterinary Surgery and Radiology, CVAS, Bikaner -334001.

Research Article

Received date: 03/07/2015

Accepted date: 19/10/2015

Published date: 22/10/2015

*For Correspondence

S K Jhirwal, Department of Veterinary Surgery and Radiology, CVAS, Bikaner -334001. Tel: +91-9414242872.

E-mail: drjhirwalsk@yahoo.co.in

ABSTRACT

Corneal ulcer is common ophthalmic affection in canines. Present study was conducted on 35 canines with different ophthalmic affections; corneal ulcer was confirmed in 5 dogs on basis of gross examination and external ophthalmic stain. Corneal ulcer was successfully managed by temporary tarsorrhaphy along with topical atropine, topical broad-spectrum antibiotic and topical Non-steroidal anti-inflammatory drugs (NSAIDs) -ketorolac. In one male dog it was treated by subconjunctival injection of serum (autologous).

INTRODUCTION

A corneal ulcer is an inflammatory condition of the cornea involving loss of its outer layer. It is very common in dogs and is sometimes seen in cats. Causes include trauma, including self-inflicted and that due to eye lid abnormalities, thermal and chemical burns, immune mediated, facial paralysis and forms of exposure keratitis and absence of the protective tear film; also infectious with bacteria, viruses and fungal elements ^[1]. Highest incidences of corneal ulcer are found Pug, Spitz, Boxer and Labrador ^[2].

MATERIAL AND METHODS

Study was conducted on 35 dogs with different ophthalmic affections presented to the Teaching Veterinary Clinical Complex (TVCC), College of Veterinary and Animal Science, Bikaner. Corneal ulcer was confirmed in 5 dogs on the basis of gross examination and fluorescein sodium stain. External ophthalmic stain (fluoresceine sodium) was used in the detection of corneal and conjunctival defects, i.e., corneal ulcer. The fluorescein sodium stain was taken up by exposed corneal stroma and appears green, helps in defining the margins the corneal ulcer. Fluorescein sodium strip was moistened with sterile 0.9% saline and touched to the dorsal bulbar conjunctiva. After the instillation of the fluorescein on the bulbar conjunctiva, the eyelids were then closed, or the patient was allowed to blink. The stain was subsequently distributed across the corneal and conjunctival surface. Eye was gently flushed after staining. It removed any excess fluorescein and simplified the diagnosis of both corneal and conjunctival lesion.

RESULTS AND DISCUSSION

In present study corneal ulcer was seen in 5 dogs out of which 2 were males and 3 were female. Fluorescein sodium strip defined the margins of the corneal ulcer. Corneal ulcers were treated by temporary tarsorrhaphy along with topical atropine (1%) 3 or 4 times a day for 3 days then once or twice a day for 1 week, topical broad-spectrum antibiotic-ciprofloxacin eye drops i.e., 4 times a day for 1 week, topical NSAIDs-ketorolac 2 times a day for 3 days. Corneal ulcer healed in 2-3 weeks period. In one male dog it was treated by subconjunctival injection of serum (autologous). All dogs recovered except one (**Figures 1 and 2**).

In present study majority of corneal ulcers were traumatic in origin and these respond well to medical therapy alone. Similar

observations were made by Hazra and Palui [3]. Ramani et al. [4] reported highest incidences of corneal ulcer in pug, spitz, boxer and Labrador. In present study the highest incidence of corneal ulcer was observed in Neapolitan mastiff followed by pug and mongrel. Corneal ulcer affected dogs had lacrimation, blepharospasm and periocular swelling as predominant clinical signs. Fluorescein stain was applied to the affected eye and diffuse corneal uptake of stain was noted. A diffused superficial corneal ulceration was diagnosed. Similar observation and diagnosis procedure was made by Brutlag et al [5]. Kern [6] reported that because of its high frequency, corneal ulceration might not routinely stimulate the clinical concern for rigorous diagnosis, attentive management and aversion of potential complications that it merits. In present study also similar observation was made and the corneal ulcers were treated with topical broad-spectrum antibiotics and topical NSAIDs along with temporary tarsorrhaphy. Healing took place in 2-3 weeks. All dogs were recovered except one. Similar treatment was advocated by Kim et al. [7] and Wilkie and Whittaker [8]. One dog was treated with autologous serum. Ben-Shlomo et al. [2] reported a non-healing corneal ulcer in a dog. Cytological testing revealed fungal hyphae (*Curvularia spp*) and extracellular cocci (*Enterococcus faecalis*). Treatment with a combination of topical antibiotics (polymyxin B, sulfate/trimetoprim and 10% sulfacetamide sodium), 1% miconazole, autologous serum, and 5% hypertonic saline was instituted. In present study the cytological testing of corneal ulcer was not performed. Dulaurent et al. [9] evaluated the efficacy of bovine pericardium (BP) graft in the treatment of deep melting corneal ulcers in dogs and corneal sequestra in cats. In present study the corneal surgery and bovine pericardium graft was not performed.

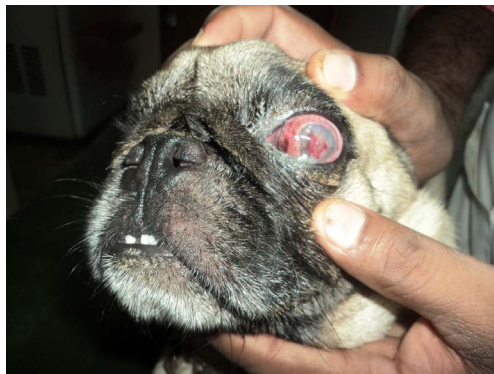
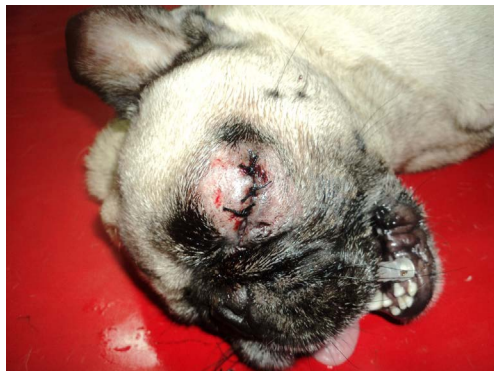

Figure 1. Corneal ulcer seen in pug.



Figures 2. Corneal ulcer treated in pug.

REFERENCES

1. Barnett KC. Diagnostic Atlas of Veterinary Ophthalmology, (2nd edn) Mosby Elsevier, USA. (2006);p.52.
2. Ben-Shlomo G, et al. *Curvularia* keratomycosis in a dog. *Veterinary Ophthalmology*. (2010); 13: 126-30.
3. Hazra S and Palui H. Grid Keratotomy for Treatment of Atypical Presenting Indolent Corneal Ulceration in a Boxer. *Nigerian Veterinary Journal*. (2011); 32: 157-159.
4. Ramani C, et al. Incidence of corneal ulcer in dogs – A retrospective study. *Tamilnadu Journal of Veterinary & Animal Sciences*. (2012); 8: 250-252.
5. Brutlag AG, et al. Corneal ulceration in a dog following exposure to the defensive spray of a walkingstick insect (*Anisomorpha spp.*) *Journal of Veterinary Emergency and Critical Care*. (2011); 21: 382-386.
6. Kern TJ. Ulcerative keratitis. *Veterinary Clinics of North America Small Animal Practice*. (1990); 20: 643-66.
7. Kim JY, et al. A Retrospective Study of Ulcerative Keratitis in 32 Dogs. *International Journal of Applied Research in Veterinary Medicine*. (2009); 7: 27-31
8. Wilkie DA and Whittaker C. Surgery of the cornea. *Veterinary Clinics of North America Small Animal Practice*. (1997); 27: 1067-107.
9. Dulaurent T, et al. Use of bovine pericardium (Tutopatch) graft for surgical repair of deep melting corneal ulcers in dogs and corneal sequestra in cats. *Veterinary Ophthalmology*. (2014); 17: 91-99.