

Non-steroidal anti-inflammatory drug-induced colopathy: A Case series

E. Iskender¹, A. Azzarok¹, CD. Gerharz², A. Sagir^{1*}

1. Department of Gastroenterology, Academic Teaching Hospital Bethesda Duisburg, Germany.

2. Department of Pathology, Academic Teaching Hospital Bethesda Duisburg, Germany.

ABSTRACT

Background: Non-steroidal anti-inflammatory drugs (NSAIDs) are regarded as one of the most widely prescribed medications for pain relief, treatment of rheumatic diseases and even available as over-the-counter medicine. Aims: Compared to the well-recognized adverse effects in upper gastrointestinal tract, the effect of such medication in colon, so called NSAID-colopathy, is increasingly described. The aim of the case series is to describe clinical presentation of NSAID-induced colopathy. Methods: Here, we present six cases with NSAID colopathy to highlight the clinical presentation and importance. Results: Our six cases of NSAID-induced colopathy presented different symptoms. Two patients consulted our clinic for abdominal pain, two because of diarrhea, one because of blood in stool, and one presented with anemia. Conclusion: NSAID-induced colopathy is an important entity of which gastroenterologists should be well aware. Based on the fact that the clinical presentations vary strongly, the diagnosis is done with a delay.

Keywords: NSAID, colopathy, stricture, ulcer

Received 13 Feb 2016

Received in revised form 27 Mar 2016

Accepted 31 Mar 2016

*Address for correspondence

A. Sagir,

Department of Gastroenterology, Bethesda Krankenhaus Duisburg, Heerstr, 219 47053 Duisburg, Germany.

E-mail: a.sagir@bethesda.de

INTRODUCTION

Since first case described by Debenham in 1966, NSAID-induced colonic damage has become a recognized entity [1]. Pathogenesis by which NSAIDs induce gastrointestinal damage is still unclear and many multifactorial local and systemic mechanisms were suggested.

Direct toxicity related to weak acidity of NSAIDs might disrupt the mucosal barrier, in addition to an increased intestinal permeability [2]. Exposure of colonic mucosa to drug after passing enterohepatic circulation was supported by the fact that endoscopic changes are mostly limited to proximal colon. From oesophagus to rectum, NSAIDs may cause mucosal injuries, its toxic effect not being dose-related [3,4]. Compared to the well-recognized adverse effects in upper gastrointestinal tract, the effect of such medication in colon, so called NSAID-colopathy, which usually involves the right colon or presents as a localized lesion in rectum, is increasingly described [4-6].

Clinical manifestation related to intake of NSAIDs can vary, some patients being asymptomatic. Others complain about non-specific symptoms like abdominal pain, or even present with iron-deficiency anaemia, A. Sagir et.al, IJPRR2016;5(3)

bloody diarrhoea, melena, blood-positive stools, weight loss or altered bowel habits mimicking inflammatory bowel disease mainly, ischemic colitis or colon cancer. In few cases, acute abdomen with intestinal obstruction or perforation can also be presenting symptoms.

In more severe complicated cases, NSAIDs abuse, may lead to pathognomonic "diaphragm disease", as a result of submucosal fibrosis leading to strictures [7].

CASE 1

A 72-year-old woman presented with abdominal pain located in the lower right quadrant for 10 days with additional pain at the defecation. The patient underwent colonoscopy 4 years ago including polypectomy. Loss of weight and blood in the stool were not observed. Due to abdominal pain the patient has taken regularly ibuprofen 400 mg for several months. The examination of the abdomen showed no pain and normal peristalsis. The blood examination was regular. Abdomen ultrasound showed only a steatosis of the liver. Upper gastrointestinal endoscopy showed *Helicobacter pylori* positive pangastritis. Triple therapy including

pantoprazole, amoxicillin and clarithromycin for 7 days was given. Colonoscopy revealed an ulcer with fibrin exudates in the terminal ileum (**Figure 1**). The macroscopic aspect of

the colon was normal. Biopsies from the terminal ileum showed a mild inflammation compatible with NSAID-induced enteropathy.

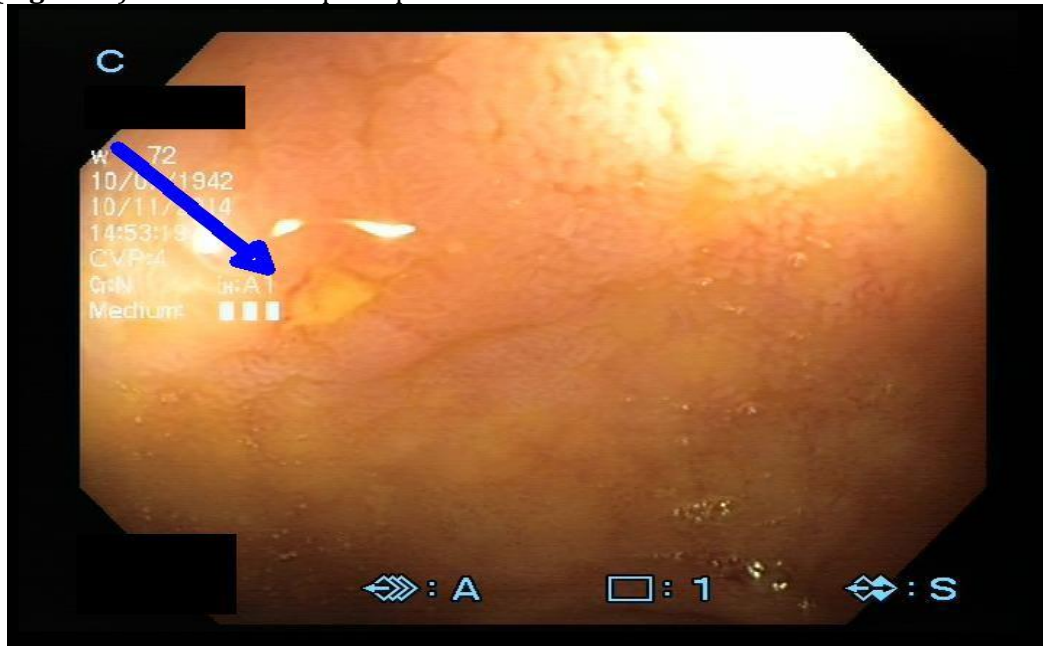

Figure 1: Finding in colonoscopy showing an ulcer with fibrin exudates in the terminal ileum.

CASE 2

A 24-year-old woman presented with pain at the lower right abdomen since 2 days. Computer tomography of the abdomen showed a thickened wall of the terminal ileum at a length of 10 cm including ileocecal valve. Additionally, several enlarged lymph nodes nearby the ileocecal valve were seen. There were no signs of appendicitis. Upper gastrointestinal endoscopy showed

Helicobacter pylori negative antral gastritis. Colonoscopy revealed multiple ulcers with fibrin exudates from terminal ileum to sigmoid (**Figure 2**). The rectum was not involved. The patient has taken diclofenac due to back pain. Biopsies of all segments beginning from terminal ileum to sigma showed an inflammation compatible with NSAID-induced enteropathy.

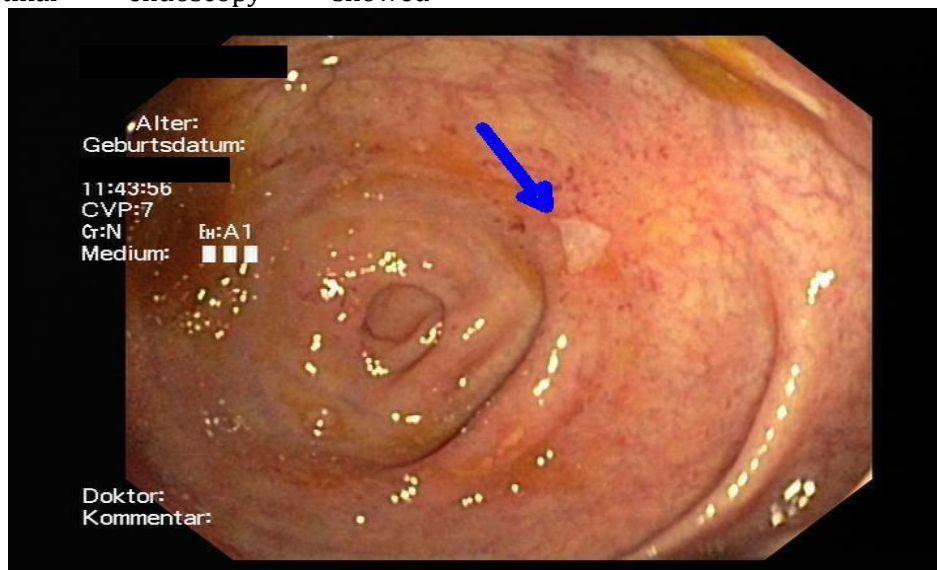


Figure 2: Finding in colonoscopy showing an ulcer in the cecum.

CASE 3

A 57-year-old woman was referred by her general practitioner because of recurrent diarrhoea. No history of abdominal pain, altered bowel habits, fever, anorexia, weight loss or previous gastrointestinal bleeding was reported. Lab tests showed no anemia or inflammation. The patient has taken diclofenac once a day due to chronic low back pain. Abdomen ultrasound was normal. There was no family history of inflammatory bowel disease or colon cancer. As part of the investigation for diarrhoea a colonoscopy was performed, which showed an ulceration in the rectum. The terminal ileum and rest of the colon appeared normal. Biopsies showed an ulcerative inflammation compatible with NSAID-induced enteropathy.

CASE 4

A 82-year-old woman presented with blood in the stool. Haemoglobin measured 10.1 g/dl and mean corpuscular volume was 87 fl. Medical history included osteoarthritis of the left hip requiring diclofenac. Abdomen was soft, non-tender and with normal bowel sound. Bleeding stopped spontaneously. Upper gastrointestinal endoscopy showed *Helicobacter pylori* negative gastritis. Colonoscopy presented ulceration in the ascending colon and one in the sigma. The

suspicion of NSAID-induced enteropathy could be confirmed by the biopsies.

CASE 5

A 71-year-old woman presented with non-bloody diarrhoea and nausea without vomiting. NSAID had been taken several times in the last month prior to admission to hospital due to chronic back pain. The blood examination showed a normocytic anemia (hemoglobin 8.2 g/dl). The patient had arterial hypertension leading to terminal dialysis-dependent kidney-insufficiency. Colonoscopy revealed an ulcerative inflammation at the ileocecal valve with a non-passable stricture. Biopsies showed a severe inflammation compatible with NSAID-induced enteropathy.

CASE 6

A 60-year-old woman presented with a severe microcytic anemia (hemoglobin 5.0 g/dl) without signs of intestinal bleeding. No abdominal pain was reported. She took regularly diclofenac due to chronic back pain. Colonoscopy showed a partly ulcerative inflammation at the ileocecal valve with a non-passable stenosis (**Figure 3**). Biopsies showed a severe, partly ulcerative, inflammation compatible with NSAID-induced enteropathy.

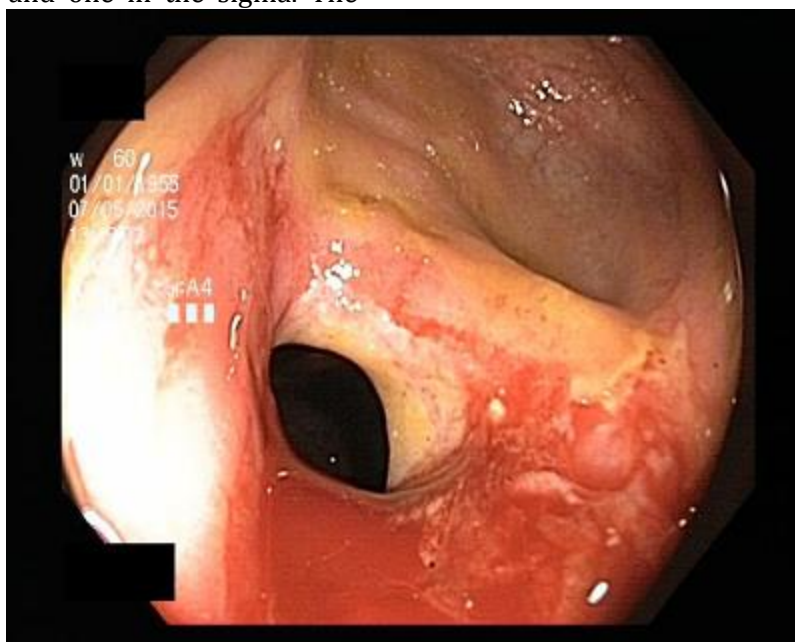


Figure 3: Finding in colonoscopy showing a partly ulcerative inflammation at the ileocecal valve with a non-passable stenosis.

DISCUSSION

NSAID are regarded as one of the most widely prescribed medications for pain relief, treatment of rheumatic diseases and are

available as over-the-counter medicine. Despite the beneficial effects associated with their long-term use such as the decrease in colorectal cancer risk and regression of existing polyps, side effects are not rare.

NSAID-induced colopathy is diagnosed based on the following criteria: (1) presence of colonic lesions confirmed by colonoscopy; (2) administration of NSAIDs before colitis; (3) absence of other diseases, such as inflammatory bowel disease, amyloidosis, infectious colitis, and ischemic colitis; and (4) confirmation of improved ulcers by repeated colonoscopy after discontinuation of NSAIDs [8,9]. We used criteria 1, 2 and 3 for the diagnosis of NSAID-induced colopathy.

Here, we would like to highlight our case series for a number of reasons (**Table 1**). First, the endoscopic findings were located from the terminal ileum to the rectum. In four cases the endoscopic findings were located only in one segment. Mucosal lesions

can be distributed continuous (case 2) but also discontinuous (case 4). NSAID induced colopathy is not rare, but diagnosis may be difficult due to the vast spectrum of clinical presentation, including inflammation, ulceration, stricture formation, bleeding, perforation, acute diarrhea, exacerbation of inflammatory bowel disease, and diaphragm-like strictures. Our six cases of NSAID-induced colopathy presented different symptoms. Two patients consulted our clinic for abdominal pain, two because of diarrhea, one because of blood in stool, and one presented with anemia. Anemia and abdominal pain were the most common reported symptoms of NSAID colopathy [10].

Table 1: Characteristics of patients with NSAID-induced colopathy, their lesions, and localization of their lesions.

Age	Gender	NSAID	Symptoms	Investigation	Localization	Lesion
72	F	Ibuprofen	Abdominal pain	Colonoscopy	Terminal ileum	Ulceration
24	F	NSAID	Abdominal pain	Colonoscopy, CT	Terminal ileum to sigma	Ulceration
57	F	Diclofenac	Diarrhoea	Colonoscopy	Rectum	Ulceration
82	F	Diclofenac	Blood in stool	Colonoscopy	Ascendens colon, sigma	Ulceration
71	F	NSAID	Nausea, diarrhoea, anemia	Colonoscopy	Ileocecal valve	Stricture, Ulceration
60	F	Diclofenac	Anemia	Colonoscopy	Ileocecal valve	Ulceration

Delay in diagnosis, which has been estimated to be 1.8 years, (range 0-15 years), although some cases were described following short-term exposure to NSAID. This delay is due to the non-specific clinical presentation. In addition, symptoms vary depending on the site of the mucosal lesion, so that there is no typical clinical leading symptom.

Another interesting point of our case series is that the age ranged from 24-82 years (mean 61 years). Manipalle analyzed 45 cases with an age ranging from 48 to 90 years [11]. Snipelisky reported NSAID colopathy in a 37 year old man with abdominal pain [12]. To our knowledge, case 2 is the youngest patient ever reported with NSAID-induced colopathy.

NSAID-induced colopathy has been described more often in women than in men. A possible reason could be that women take NSAID more often, but genetic susceptibility has to be discussed as well. The pathogenesis of NSAID-induced colopathy is not clear, but

prostaglandins (PGs) seem to be involved. Prostaglandins (PG) play a critical role in maintaining the mucosal defense system. Inhibition of COX leading to decreased mucosal PGs is considered as the most important factor in the pathogenesis of NSAID-induced mucosal damage [13-15]. Old people and patients on long-term treatment are considered to be high risk groups.

Confusional macroendoscopic pictures leading to the misdiagnosis of inflammatory bowel disease and ischemic colitis as well as misinterpretation of histopathology is not infrequent. Awareness of the clinical, endoscopic, and histopathologic aspects of NSAID-induced colopathy as well as detailed medical drug history is therefore necessary. Histopathologic findings of ischemic-type necrosis in the biopsy should raise the suspicion of NSAID colopathy [10].

The endoscopic picture includes solitary or multiple erosions, ulcerations, strictures, and sometimes pathognomic diaphragm-like

strictures. These findings are restricted predominantly to the right-sided colon. Early detection of this disease helps in prevention of further progression.

There is actually no way to prevent NSAID-induced colopathy. Prevention of NSAID-induced colopathy by routine addition of misoprostol seems not to be successful. Some studies showed successful treatment with sulphasalazine and metronidazole. Therefore, discontinuation of NSAID use or at least dose reduction is the main principle of treatment. This action has been shown to resolve the symptoms resulting from inflammation associated colonic diaphragms within a short period of time. However, scarred lesions with stricture formation fail mostly to heal and mandate endoscopic intervention e.g. pneumatic dilatation and placement of a metal stent or even surgical resection [16-18].

Kurahara et al. described 13 patients with NSAID-induced uncomplicated ulceration. In all cases ulceration healed had upon repeat colonoscopy at 3-10 weeks after withdrawal of the NSAID without stricture [9]. Other medical therapies that showed promising results were steroids and 5-aminosalicylic acid [19-21].

COX-2 inhibitors lack some side effects of the NSAID, but there is little available evidence on their possible side effect on colon [22]. There are case reports of acute hemorrhagic colitis under rofecoxib therapy, which resolved after stopping the therapy.

CONCLUSION

NSAID induced colopathy is not rare, but diagnosis may be difficult due to the vast spectrum of clinical presentation. Delay in diagnosis is due to the non-specific clinical presentation. Awareness of the clinical, endoscopic, and histopathologic aspects of NSAID-induced colopathy as well as detailed medical drug history is therefore necessary. There is actually no way to prevent NSAID-induced colopathy. Therefore, discontinuation of NSAID use or at least dose reduction is the main principle of treatment.

REFERENCES

1. Debenham GP. Ulcer of the cecum during oxyphenbutazone (tandearil) therapy. *Can Med Assoc J.* 1966; 28: 1182-1184.
2. Matsui H, Shimokawa O, Kaneko T, Nagano Y, Rai K, Hyodo I. The pathophysiology of non-steroidal anti-inflammatory drug (NSAID)-induced mucosal injuries in stomach and small intestine. *J Clin Biochem Nutr.* 2011; 48: 107-111.
3. Gleeson MH, Davis AJ. Non-steroidal anti-inflammatory drugs, aspirin and newly diagnosed colitis: A case-control study. *Aliment Pharmacol Ther.* 2003; 17: 817-825.
4. Sostres C, Gargallo CJ, Arroyo MT, Lanas A. Adverse effects of nonsteroidal anti-inflammatory drugs (NSAIDs, aspirin and coxibs) on upper gastrointestinal tract. *Best Pract Res Clin Gastroenterol.* 2010; 24: 121-132.
5. Geramizadeh B, Taghavi A, Banan B. Clinical, endoscopic and pathologic spectrum of non-steroidal anti-inflammatory drug-induced colitis. *Indian J Gastroenterol.* 2009; 28: 150-153.
6. Ballinger A. Adverse effects of nonsteroidal anti-inflammatory drugs on the colon. *Curr Gastroenterol Rep.* 2008; 10: 485-489.
7. Lang J, Price AB, Levi AJ, Burke M, Gumpel JM, Bjarnason I. Diaphragm disease: pathology of disease of the small intestine induced by non-steroidal anti-inflammatory drugs. *J Clin Pathol.* 1988; 41: 516-526.
8. Matsumoto T, Iida M, Kurahara K. Clinical and endoscopic features in patients with nonsteroidal anti-inflammatory drug-induced colopathy. *Stomach and Intestine.* 2000; 35: 1147-1158.
9. Kurahara K, Matsumoto T, Iida M, Honda K, Yao T, Fujishima M. Clinical and endoscopic features of nonsteroidal anti-inflammatory drug-induced colonic ulcerations. *Am J Gastroenterol.* 2001; 96: 473-480.
10. Stolte M, Karimi D, Vieth M, Volkholz H, Dirschmid K, Rappel S, et al. Strictures, Diaphragms, Erosions or Ulcerations of Ischemic Type in the Colon Should Always Prompt Consideration of Nonsteroidal Anti-Inflammatory Drug-Induced Lesions. *World J Gastroenterol.* 2005; 11: 5828-5833.
11. Munipalle PC, Garud T, Light D. Diaphragmatic disease of the colon: systematic review. *Colorectal Dis.* 2013; 15: 1063-1069.

12. Snipelisky DF, Cable CA, Maniaci MJ. 37-Year-Old Man with Abdominal Pain. *Mayo Clin Proc.* 2014; 89: 558-562.
13. Cryer B, Spechler SJ. Peptic ulcer disease. *Sleisenger and Fordtran's Gastrointestinal and Liver Disease (8th edn)*. Philadelphia: Saunders. 2006; 1089-1110.
14. Kargman S, Charleson S, Cartwright M, Frank J, Riendeau D, Mancini J, et al. Characterization of Prostaglandin G/H Synthase 1 and 2 in rat, dog, monkey, and human gastrointestinal tracts. *Gastroenterology.* 1996; 111: 445-454.
15. Wallace JL, McKnight W, Reuter BK, Vergnolle N. NSAID-induced gastric damage in rats: requirement for inhibition of both cyclooxygenase 1 and 2. *Gastroenterology.* 2000; 119: 706-714.
16. Kaufman HL, Fischer AH, Carroll M, Becker JM. Colonic ulceration associated with nonsteroidal anti-inflammatory drugs. Report of three cases. *Dis Colon Rectum.* 1996; 39: 705-710.
17. Israel LH, Koea JB, Stewart ID, Wright CL, Frankish PD. Nonsteroidal anti-inflammatory drug-induced strictures of the colon: report of a case and review of the literature. *Dis Colon Rectum.* 2001; 44: 1362-1364.
18. Spirnak JP, Monahan DW. Colonic diaphragms associated with long-term use of nonsteroidal anti-inflammatory drugs. *AJR Am J Roentgenol.* 1993; 160: 1148-1149.
19. Halter F, Weber B, Huber T, Eigenmann F, Frey MP, Ruchti C. Diaphragm disease of the ascending colon. Association with sustained-release diclofenac. *J Clin Gastroenterol.* 1993; 16: 74-80.
20. Weinstock LB, Hammoud Z, Brandwin L. Nonsteroidal anti-inflammatory drug-induced colonic stricture and ulceration treated with balloon dilatation and prednisone. *Gastrointest Endosc.* 1999; 50: 564-566.
21. Penner RM, Williams CN. Resolution of multiple severe nonsteroidal anti-inflammatory drug-induced colonic strictures with prednisone therapy: a case report and review of the literature. *Can J Gastroenterol.* 2003; 17: 497-500.
22. Wight NJ, Gottesdiener K, Garlick NM, Atherton CT, Novak S, Gertz BJ, et al. Rofecoxib, a COX-2 inhibitor, does not inhibit human gastric mucosal prostaglandin production. *Gastroenterology.* 2001; 120: 867-873.