

Spinal Cord Tumours: A Review article

Jayashree Padhy*

*Department of Biotechnology, GITAM University, GIT, Visakhapatnam, Andhra Pradesh, India

Research Article

Received: 02/02/2017

Revised: 23/02/2017

Accepted: 28/02/2017

*For Correspondence

Jayashree Padhy, M.Tech,
Department of Biotechnology,
Arthur Cotton Bhavan, GIT,
GITAM, Rushikonda,
Visakhapatnam-530045, Andhra
Pradesh, India.

E-mail:

padhy.jayashree@gmail.com

Keywords: Spine, Bones,
Decompression

ABSTRACT

[Spinal](#) line tumors may create inside the spinal string parenchyma, straightforwardly obliterating tissue, or outside the line parenchyma, regularly packing the string or nerve roots. Side effects incorporate dynamic back agony and neurologic deficiencies referable to the spinal string or spinal nerve roots. Analysis is by MRI. Treatment may incorporate corticosteroids, surgical extraction, and radiation treatment.

INTRODUCTION

[Spinal Tumors](#) of the spine are effectively named extradural, intradural/extramedullary, and [intramedullary](#). As to tumors as a rule, extradural injuries happen most regularly and most are metastatic. Of the intradural sores (which are uncommon), 84% are extramedullary, the dominant part being nerve sheath tumors or meningiomas. Around 16% of intradural tumors are intramedullary, the most well-known being ependymoma trailed by astrocytoma. An essential spinal tumor implies it originates from cells inside or close to the spine. They can include the spinal line, nerve roots, and additionally the vertebrae (bones of the spine) and pelvis [1-9]. They can be considerate (non-carcinogenic) or harmful (dangerous). As a rule, kindhearted tumors don't attack different tissues. Threatening tumors may attack different tissues and organs in the body. Albeit essential spinal tumors regularly contain various unusual qualities their cause stays obscure. Now and again the tumors keep running in families. Tumors in the spine turn into an issue when they pack the spinal rope or nerves. This can prompt to genuine inconveniences, for example, loss of motion and loss of bladder and gut control. Others can wreck the vertebral bone that backings the spinal string making it insecure [9-15]. An [auxiliary spinal tumor](#) is more normal. This implies the tumor went there from malignancy elsewhere in the body. These optional or metastasized tumors are constantly dangerous. These malignancy cells travel and cause tumors that normally include the vertebrae or hard bit of the spine. They may originate from melanoma (skin malignancy), growth in the lung, bosom, prostate, kidney, or thyroid organ for instance.

[Spinal tumors](#) infrequently happen and are either benevolent or threatening. A few tumors are known to metastasize (spread) through corridors, veins, the lymphatic framework, and specifically. Dangerous tumors of the

bosom, prostate, lung, and kidney can spread into the spine. Spinal tumors can be risky when they cause spinal trench pressure, which may prompt to neurologic brokenness (e.g., loss of motion) [16-23].

Numerous patients will give back torment as the essential indication. The torment can happen very still, be more terrible during the evening, and could conceivably be identified with movement. Different indications may incorporate sciatica, deadness, paraparesis (slight loss of motion), spinal disfigurement (eg, scoliosis, kyphosis), and fever [24-29].

The [American Chiropractic Association](#) reports that around 31 million Americans experience the ill effects of lower back torment. What's more, back torment is the main source of inability around the world.

Intramedullary tumors

The most widely recognized are gliomas (e.g., ependymomas, poor quality astrocytomas).

Intramedullary tumors invade and devastate rope parenchyma; they may reach out over different spinal line sections or result in a syrinx (see Syrinx of the Spinal Cord or [Brain Stem](#)) [30-37].

Extramedullary tumors: These tumors might be intradural or extradural. Most intradural tumors are kind, typically meningiomas and neurofibromas, which are the most well-known essential spinal tumors. Most extradural tumors are metastatic, for the most part from carcinomas of the lungs, bosoms, prostate, kidneys, or thyroid or from lymphoma (eg, Hodgkin lymphoma, lymphosarcoma, reticulum [cell sarcoma](#)) [38-44].

Intradural and extradural tumors cause neurologic harm by packing the spinal rope or nerve roots. Most extradural tumors attack and pulverize bone before packing the string.

Symptoms

Agony is an early indication, particularly for [extradural tumors](#). It is dynamic, disconnected to movement, and intensified by supineness [45-53]. Agony may happen in the back, transmit along the tangible circulation of a specific dermatome (radicular torment), or both. Generally, neurologic shortages referable to the spinal string in the long run create. Regular illustrations are spastic shortcoming, incontinence, and brokenness of a few or the greater part of the tangible tracts at a specific fragment of the spinal rope and beneath. Deficiencies are normally reciprocal [54-63].

Numerous patients with [extramedullary tumors](#) give torment, however some present with tactile shortfalls of the distal lower furthest points, segmental neurologic deficiencies, indications of spinal line pressure, or a blend [64-72]. Manifestations of spinal rope pressure can intensify quickly and result in paraplegia and loss of entrail and bladder control. Indications of nerve root pressure are additionally normal; they incorporate torment and paresthesias took after by tactile misfortune, strong shortcoming, and, if pressure is perpetual, muscle squandering, which happens along the circulation of the influenced roots [73-80].

Treatment

- Corticosteroids
- Extraction, radiation treatment, or both

For patients with neurologic shortfalls, corticosteroids (e.g., dexamethasone 100 mg IV, then 10 mg po qid) are started instantly to decrease spinal line edema and save work. Tumors compacting the [spinal rope](#) are dealt with as quickly as time permits [81-85].

Some all-around limited essential spinal line tumors can be extracted surgically. Deficiencies resolve in about portion of these patients. On the off chance that tumors can't be surgically extracted, radiation treatment is utilized, with or without surgical decompression. Compressive metastatic extradural tumors are normally surgically extracted from the [vertebral body](#), then treated with radiation treatment. Non-compressive metastatic extradural tumors might be treated with radiation treatment alone yet may require extraction if radiation treatment is incapable [86-90].

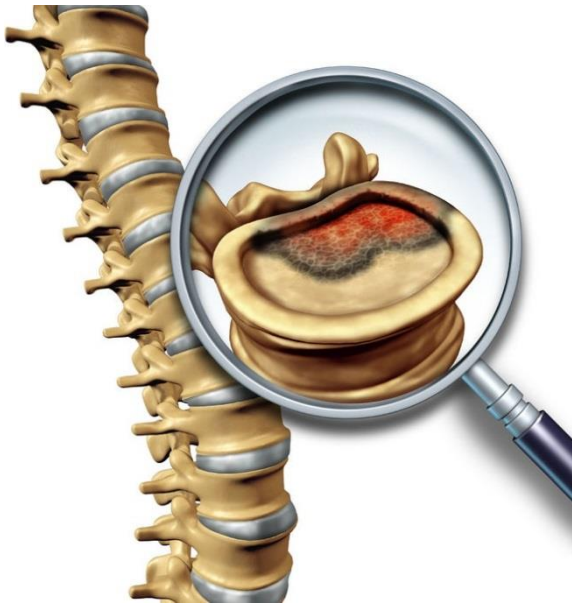

Figure 1: Spinal cord showing the spinal tumor.

Essential spinal tumors fall into an unmistakable classification in light of the fact that their opportune finding and the prompt establishment of treatment enormously affect the patient's general guess and seek after a cure ^[90-94].

For the most part, with spinal pathology, issues that emerge are either [interminable issues](#) identified with degenerative illness or deformation or intense signs of traumatic sequelae. While considering tumors of the spine, one must consider the diverse tissue sorts around the spinal section (**Figure 1**). The nearness of neural tissue, meningeal tissue, bone, and ligament makes any of these tissue sorts a conceivable nidus for neoplastic change. Additionally, metastatic sores may spread to the spine from far off essential tumor locales by hematogenous or [lymphatic courses](#) ^[95-97].

Essential non-[lymphoproliferative tumors](#) of the spine are exceptional and make up less than 5% of bone neoplasms, representing less than 2.5-8.5 essential spine tumors for every 100,000 individuals for each year. Metastatic malady of the spine is significantly more normal. Around 40-80% of patients who pass on of growth have hard metastases at the season of death, with the spine being the most widely recognized metastatic skeletal area (**Figure 2**) ^[98-100].

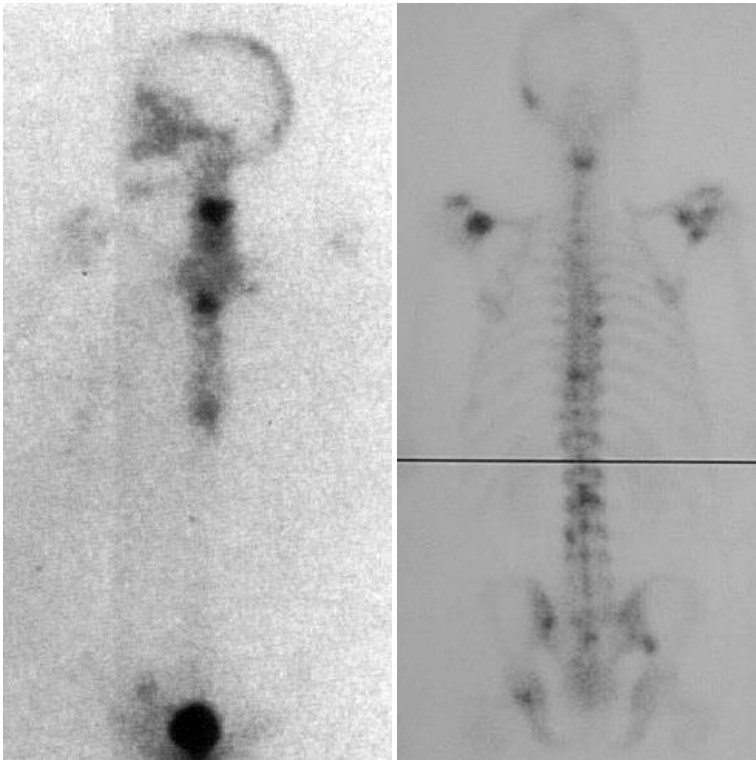


Figure 2: Unilateral view of Spinal cord identifying the spinal tumor.

DISCUSSION

This refinement in some cases can be hard to make as a result of the confounded engineering of the spine. The doctor must consider differential analyses of degenerative procedures in [Chiropractors](#), diseases, solid strains, neurologic impingements, and, at long last, neoplastic procedures. With exhaustive history taking, physical examination, and indicative [imaging](#), the doctor can procure enough data to proficiently in [Spinal Decompression](#) make the right finding [spinal segment](#) ^[101-102].

CONCLUSION

[Neoplastic sickness](#), notwithstanding, can give back agony that is unclear from back torment coming about because of more kind causes. Along these lines, the doctor tending to patients griping of back torment is confronted with the test of recognizing considerate causes from those that can be neurologically or systemically annihilating and endorsing the proper treatment.

REFERENCES

1. Anke Scheel-Sailer, et al. The Future of Clinical Research in the Field of Spine. *J Spine* 2015;4:e116.
2. Reinard KA, et al. Intradural Tophaceous Gout of the Cavernous Sinus and Spine: Case Report and Review of Literature. *J Neurol Disord.* 2015;3:234.
3. Tarek Sunna P, et al. Intradural Lumbar Disc Herniation Associated with degenerative Spine Disease. *Int J Neurorehabilitation Eng.* 2015;2:153.
4. Alessandro Landi, et al. Facet Wedge Fixation in Lumbar Spine Degenerative Pathology: A New Option for Minimally-Invasive Posterior Approach?. *Orthop Muscul Syst.*
5. Yusuf Muhammed Durna, et al. The Case of Papillary Thyroid Carcinoma Presented with Lumbar Spine Metastasis. *Otolaryngol (Sunnyvale).* 2015;5:89.
6. Umesh C Parashari, et al. A Rare Case of Renal Cell Carcinoma in Left Renal Ectopia with Cervical Spine Metastasis Presented as Quadriplegia. *Med Surg Urol.* 2014;4:149.

7. Francesco Travascio, et al. Implications of Decompressive Surgical Procedures for Lumbar Spine Stenosis on the Biomechanics of the Adjacent Segment: A Finite Element Analysis. *J Spine*. 2015;4:220.
8. Mende KC, et al. Comparison of Dual Level Fusion and Hybrid Treatment in the Cervical Spine Based on Patient Outcome. *J Spine*. 2015;4:218.
9. Marcelo Wajchenberg, Michel Kanas, Delio E Martins, Luciano Miller Reis Rodrigues, Reinaldo Jesus Garcia and Eduardo Barros Puertas, et al. Chordoma of the Cervical Spine in a Competition Athlete: Case Report and Long-term Follow Up. *J Spine*. 2015;4:216.
10. Shamim Ahmad Bhat, et al. Concomitant Pyogenic Spondylodiscitis with Large Psoas Abscess in Known Case of Tuberculosis Spine; Presenting as Refractory Tuberculosis. *J Spine*. 2015;4:212.
11. Mehmet Resid Onen, et al. Pediatric Spine Trauma. *J Spine*. 2015;4:211.
12. Balioglu MB, et al. Escobar Syndrome Associated with Spine and Orthopedic Pathologies: Case Reports and Literature Review. *Hereditary Genet* 2015;4:45.
13. Kumar saurav, et al. Synthesis and Processing of Zirconia- Spinel Refractory Ceramics. *IJRSET*.
14. Desmoulin GT, et al. A Biomechanical Method for Reconstruction of Tumbling Trampoline- Associated Cervical Spine Injuries Using Human and Anthropometric Test Dummy Data. *Journal of Forensic Biomechanics*.
15. Lolwah Ahmad Al-Rashed, et al. Effectiveness of Non-Pain-Contingent Spine Rehabilitation in Females with Chronic Low Back Pain: A Randomized Controlled Trial. *Int J Phys Med Rehabil*. 2015;3:260.
16. Robyn Rubenstein, et al. Thoracolumbar Injury Severity Scoring Systems: A Review and Rationale for a New System Based on the AOSpine Thoracolumbar Injury Classification System. *Int J Phys Med Rehabil* 2015;3:257.
17. Akbar Shoukat Ali, et al. Intradural Extramedullary Ependymoma at Lumbar (L1-L4 Level) Spine: A Suspicious Case and Literature Review. *J Clin Case Rep*. 2015;5:572.
18. Abiola O Ogundele, et al. Influence of Selected Pain Characteristics on Segmental Spine Range of Motion in Patients with Low-Back Pain. *J Ergonomics*. 2015;5:138.
19. Claudio Spinelli, et al. Habitual Joint Dislocations and Recurrent Multiple Hernias: An Unusual Connective Tissue Disease?. *J Clin Case Rep*. 2015;5:563.
20. Chougule VN, et al. Patient Specific Bone Modeling for Minimum Invasive Spine Surgery. *J Spine*. 2015;4:249.
21. Gun Choi, et al. Motion Preserving Techniques for Treating Cervical Radiculopathy. *J Spine*. 2015;4:247.
22. Salkov M, et al. The Method of Multilevel Decompression of Thoracic Spine with the Durotomy and the Local Administration of Cortixin in the Setting in Intradural Space in the Patients with Spinal Cord Injury. *Int J Neurorehabilitation Eng*. 2015;2:173.
23. Luiz Pimenta, et al. Minimally Invasive Lateral Approach to the Thoracic Spine Case Report and Literature Overview. *J Spine*. 2015;4:240.
24. Jose Antonio Becerra Fontal, et al. Evaluation of Health Related Quality of Life in Patients Candidate for Spine Surgery. *J Spine*. 2015;4:239.
25. Azedine Medhkour, et al. Acute Left-sided Foot Drop Attributed to Recurrent Synovial Chondromatosis of the Lumbar Spine. *J Spine*. 2015;4:230.
26. Sharma A, et al. Cellular Therapy, a Novel Treatment Option for Intellectual Disability: A Case Report. *J Clin Case Rep*. 2015;5:483.
27. Andrei V. Baskov, Igor A. Borshchenko, Anatoly B. Shekhter, Vladimir A. Baskov, Anna E. Guller Sobol, et al. Long Term Clinical Results in Laser Reconstruction of Spine Discs. *J Spine* 2015;4:210.
28. Roger Marks, et al. Use of Dexmedetomidine (Precedex) for Spine Surgery. *J Spine*. 2015;4:e115.
29. Benyahia N-M, Breebaart MB, Sermeus L and Vercauteren M, et al. (2015) Regional Analgesia Techniques for Spine Surgery: A Review with Special Reference to Scoliosis Fusion. *J Spine* 2015;4:208.
30. Justin Magee, et al. (2015) Three Dimensional Digital Modelling of Human Spine Anthropometrics and Kinematics from Meta-Analysis. How Relevant is Existing Anatomical Research?. *J Spine*. 2015;4:205
31. Jie Zhu, et al. Leukocytosis of Unknown Etiology in a Patient with a Spinal Cord Stimulator. *J Spine*. 2015;4:204.
32. Jie Zhu, et al. A Review of Surgical Techniques in Spinal Cord Stimulator Implantation to Decrease the Post-Operative Infection Rate. *J Spine*. 2015;4:202.
33. Paul Mintken, et al. Shoulder Pain and Regional Interdependence: Contributions of the Cervicothoracic Spine. *J Yoga Phys Ther*.

34. Quan V Vuong, et al. Phenolic Compounds, Antioxidant and Anti-Cancer Properties of the Australian Maroon Bush *Scaevola spinescens* (Goodeniaceae). *J Bioanal Biomed.* 2015.
35. Bouali Sofiene, et al. Primary Spinal Epidural Rhabdomyosarcoma of the Upper Thoracic Spine. *J Spine.* 2014;3:193.
36. Hamaoui A, et al. Seat Design, Spine Curvature and Intradiscal Pressure. *J Ergonomics.* 2014;4:e124.
37. Archana Rani, et al. Complete Non-fusion of the Sacral Spines: A Rare Phenomenon. *Medical and Health Sciences.*
38. Damandeep Kour, et al. Variation in the Kinematic Response of Cervical Spine, Proprioception and Muscle Activity During Anterior Load Carriage-An Experimental Study. *J Nov Physiother* 2014;4:236.
39. Kanthika Wasinpongwanich, et al. Are Deer and Boar Spines a Valid Biomechanical Model for Human Spines?. *J Spine.* 2014;3:187.
40. Enrico Farabegoli, et al. Dragging Instead of Lifting: A New Spine Stretcher Concept. *J Spine.* 2014;3:183.
41. Billy B Kristensen, et al. High-Volume Infiltration Analgesia in Major Lumbar Spine Surgery. A Randomized, Placebo-Controlled, Double-Blind Trial. *J Anesth Clin Res.* 2014;5:450.
42. Jerome Fryer, et al. The Hypnic Reflex, Postulated to be a Monosynaptic Reflex Generated from Spine Stretching as the Muscles Relax around the Intervertebral Discs. *J Sleep Disord Ther.* 2014;3:102.
43. Jose Aso-Escario, et al. Upper Thoracic Spine Fractures Treated by Posterior Transpedicular Corpectomy, Expandable Cage and Fusion: Literature Review and Report of a Case of T4 Severe Burst Fracture. *Int J Neurorehabilitation Eng.* 2014;1:117.
44. Joaquim Soares Do Brito, et al. Extensive Involvement of the Dorsal Spine by Tuberculous Infection and Surgical Treatment with Percutaneous Spinal Instrumentation. *J Infect Dis Ther.* 2014;2:156.
45. Lars Homagk, et al. Therapy of Spine Metastasis Causing Paralysis Symptoms "Operation and Rehabilitation. *Surgery.* 2014;10:2.
46. Alok Sharma, et al. Seizures as an Adverse Event of Cellular Therapy in Pediatric Neurological Disorders and its Prevention. *J Neurol Disord.* 2014;2:164.
47. Christopher Yeung, et al. Clinical Validation of Allogeneic Morphogenetic Protein: Donor Intersubject Variability, Terminal Irradiation and Age of Product is not Clinically Relevant. *J Spine.* 2014, 3: 173.
48. Hai Le, et al. Cervical Spine Ependymoma with Hematomyelia: Case Report and Review of the Literature. *J Spine.* 2014;3:171.
49. Frank Spinelli, et al. The Sexually Abused Man's Relationship with his Physician. *J Clin Case Rep.* 2016;6:893.
50. Alessandro Landi, et al. The Anterior Retroperitoneal Approach to the Degenerative Lumbar Spine: Clinico-Therapeutic Remarks. *J Spine.* 2016;5:347.
51. Nalinee Kovitwanawong, et al. A Comparison of Cervical Spine Movement during Tracheal Intubation when Using a Pentax Airway Scope or the GlideScope Video Laryngoscopy with Fluoroscopy. *J Anesth Clin Res.* 2016.
52. Gun Choi, et al. Epiduroscopic Assisted Percutaneous Endoscopic Lumbar Discectomy: A Technical Report. *J Neurol Disord.* 2016;4:306.
53. Anthony T Yeung, et al. Current Defies of Neurological Disorders. *J Neurol Disord.* 2016, 4: e120.
54. Tulay Ozer, et al. Computed Tomographic Evaluation of Degenerative Spine Changes in Patients with Obstructive Sleep Apnea Syndrome: A Case Control Study. *J Sleep Disord Ther.* 2016;5:253.
55. Rahul Pramod Patil, et al. Comparative Study Between Short Segment Open Versus Percutaneous Pedicle Screw Fixation with Indirect Decompression in Management of Acute Burst Fracture of Thoracolumbar and Lumbar Spine with Minimal Neurological Deficit in Adults. *J Spine.* 2016;5:339.
56. Bahaa Ali kornah, et al. Minimally Invasive Spine Osteosynthesis (MISO) Technique for Fractures Spine: A Case Series 14 Cases. *J Trauma Treat.* 2016;5:336.
57. Suha N Aloosi, et al. Contribution of Cervical Spine in Temporomandibular Joint Disorders: A Cross-Sectional Study. *J Interdiscipl Med Dent Sci.*
58. Anthony T Yeung, et al. Transforaminal Endoscopic Surgery: Its Role in the Treatment of Painful Conditions of an Aging Spine. *J Neurol Disord.* 2016;4:302.
59. Samir Zahaf, et al. The Effect of the Posterior Loading on the Spine of a School Child. *Adv Cancer Prev.* 2016;1:112.
60. Gun Choi, et al. A New Progression Towards a Safer Anterior Percutaneous Endoscopic Cervical Discectomy: A Technical Report. *J Spine.* 2016;5: 329.

61. Tongning Wang, et al. Tuberculous Pseudoaneurysm of Descending Abdominal Aorta in Association with Tuberculosis of Spine: A Rare Complication. *Vasc Med Surg.* 2016;4:279.
62. Mahesh BH, et al. Emphysematous Osteomyelitis - A Rare Cause of Gas in Spine - A Case Report. *J Spine.* 2016;5:320.
63. Dulce A Velázquez-Zamora, et al. Administration of Anastrozole to Ovariectomized Rats Impairs Working Memory in Association with Plastic Changes to Dendritic Spines on Prefrontal Third-layer Pyramidal Neurons. *J Steroids Horm Sci.* 2016;7:179.
64. Paul S Sung, et al. One Leg Standing Test: A Quantification of the Neuromuscular System for Spine Research and Practice. *J Pain Relief.* 2016;5:256.
65. Maria Jose Moreno Martinez, et al. Spine Fracture in Ankylosing Spondylitis. About a Case. *Rheumatology (Sunnyvale).*
66. Akihiko Hayashi, et al. Microendoscopic Posterior Decompression for the Treatment of Lumbar Lateral Recess Stenosis. *J Spine.* 2016;5:317.
67. Maximilian Leiblein, et al. Transmanubrial Approach for Fracture of Lower Cervical Spine (C7) in Elderly Patients: A Case Report. *J Spine.* 2016;5:316.
68. Alessandro Ramieri, et al. Non-Posterior Subtraction Osteotomy Surgery to Restore Lumbar Lordosis in the Hidden Sagittal Imbalance of the Adult Degenerative Spine. *J Spine* 2016;5:315.
69. Yan Wang, et al. Evaluation of Progression of Ossification of Ligamentum Flavum in the Thoracic Spine Using Computed Tomography. *J Spine.* 2016;5:306.
70. Bolandhemat N, et al. Structural, Electronic and Magnetic Properties of Geometrically Frustrated Spinel CdCr₂O₄ from First-principles Based on Density Functional Theory. *J Material Sci Eng.* 2016;5:250.
71. Wood ML, et al. Cervical Spine Synovial Chondromatosis: A Case Report and Literature Review. *Med Rep Case Stud.* 2016;1:114.
72. Alok Sharma, et al. PET - CT Scan Shows Decreased Severity of Autism after Autologous Cellular Therapy: A Case Report. *Autism Open Access.*
73. Neisevilie Nisa, et al. Anaesthetic Management of an Achondroplastic Dwarf with Difficult Airway and Spine for Total Hip Replacement: A Case Report. *Gen Med.* 2016.
74. Alessandro Landi, et al. Early Decompressive Surgery in Traumatic Thoraco-Lumbar Spine: When and Why?. *J Spine.* 2016;5:301.
75. Anne-Laure Couderc, et al. Prognostic Factors in Elderly Patients with Multiple Myeloma Treated with Weekly Bortezomib. *J Integr Oncol.* 2016;5:162.
76. Yonge RP, et al. Frailty Screening and Pre-rehabilitation in Older Spine Patients Reversing the Effects of Sedentary Life-styles to Improve Surgical Outcomes for Older Patients and Reduce Healthcare Costs. *J Osteopor Phys Act.* 2016;4:171.
77. Andrey Bokov, et al. Pedicle Screw Loosening Prediction in Patients with Degenerative Diseases of Lumbar Spine Using Bone Density Measured in Hounsfield Units. *J Osteopor Phys Act.* 2016;4:162.
78. Jung-Hee Lee, et al. Intraosseous Malignant Peripheral Nerve Sheath Tumor of the Thoracic Spine: A Case Report and Review of Literature. *J Orthop Oncol.*
79. Stephen Lewis, et al. Traumatic Disc Herniation Following Flexion-Distraction Injury of the Thoracolumbar Spine: A Rare Presentation. *J Trauma Treat.* 2016;5:293.
80. Shein AP, et al. The Spinal Cord Pyramidal Structures Reaction to Intraoperative Instrumental Correction of Spine Deformity. *J Spine* 2016;5:292.
81. Ashraf F Hanna, et al. Intravenous Ketamine Produces Long-Term Pain Relief in a Patient with Fibromyalgia. *Fibrom open.* 2016;1:104.
82. Yasuhito Kaneko, et al. Minimally Invasive Transforaminal Lumbar Interbody Fusion for Lumbar Disc Lesion with Modic Changes. *J Spine.* 2016;5:289.
83. Ramesh Muthu, et al. A Missed Diagnosis of Cervical Spine Fracture in Alcohol Intoxicated Patient. *Emerg Med.* 2016;6:300.
84. Teresa Calabro, et al. Systemic Amyloidosis with Predominant Spine Involvement: A Case Report. *Orthop Muscular Syst.* 2016.
85. Óscar García- Algar, et al. Genomic Alterations in Ethanol-Exposed Trophoblast Cell Lines Induced by Chronic Ethanol Treatment. *J Steroids Horm Sci.* 2015;6:164.

86. Anthony T. Yeung, et al. Moving Away from Fusion by Treating the Pain Generator: The Secrets of an Endoscopic Master. *J Spine*. 2015;4:e121.
87. Chan Hong Park, et al. Efficacy of Nucleo-Annuloplasty Using Disc-Fx in Lumbar Disc Herniation. *J Spine*. 2015;4:275.
88. Geniere Nigrag S, et al. Picked Up by a Wasp? Watch Out the Spine! A Case of Multifocal Pyogenic Spondylodiscitis. *J Clin Case Rep*. 2015;5:627.
89. Makhlouf MT, et al. Nano-Crystalline Co3O4 Spinel Prepared by Combustion Method as a Catalyst for Direct Decomposition of N2O. *Journal of Chemistry*.
90. Mohammed YTA, et al. Utilization of Intra-Operative Visual Evoked Potential in Long Spine Surgery: Case Report. *J Neurol Neurophysiol*. 2015;6:332.
91. Massel DH, et al. Multimodal Analgesia in Spine Surgery: A Commentary. *J Pain Relief*. 2015;4:218.
92. Andarcia Bañuelos Cesar, et al. A Rare Complication of Lumbar Spine Surgery: Pneumocephalus. *J Spine*. 2015;S6-001.
93. Luca di Girolamo, et al. Blood Volume Determination Through New Generation 130/0,4 Hydroxyethyl-Starch: A Propaedeutic, In-Vitro Study. *Pharm Anal Acta*. 2015;6:441.
94. Ozgur Tosun, et al. Penetrating Stab Injury of Spine; Diagnostic Value of Thin-Section Multislice Computed Tomography. *J Spine*. 2015;4:264.
95. Qingyi He, et al. Can XLIF Surgery Treat the Lumbar Spine Infection?. *J Trauma Treat*. 2015;4:264.
96. Akbar Shoukat Ali, et al. Intradural Extramedullary Ependymoma at Lumbar (L1-L4 Level) Spine: A Suspicious Case and Literature Review. *J Clin Case Rep*. 2015;S3:004.
97. Myung-Sang Moon, et al. Age-Related Incidences of Spondylosis of the Lower Cervical Spine Radiographic Study of 460 Jeju Islanders. *J Spine*. 2015;4:258.
98. Kingsley RC, et al. Avoidance of Wrong Level Surgery in the Lumbar Spine: A Technical Report. *J Spine*. 2015;4:257.
99. Pawel Zwolak, et al. Management of Metastatic Tumours to the Cervical Spine. *J Spine*. 2015;4:253.
100. Nikola Dragojlovic, et al. Communicating Hydrocephalus due to Traumatic Lumbar Spine Injury: Case Report and Literature Review. *Int J Phys Med Rehabil*. 2015;3:299.
101. Chen CW, et al. Surgical Site Infection Following Spine Surgery: Diagnostic Potential of CRP, ESR, and WBC in Predicting Infection. *Emerg Med*. 2015;5:277.
102. Ahimsa Porter Sumchai, et al. The Human Spine is like a Precious Strand of Pearls. *J Women's Health Care*. 2015;4:258.