



International Journal of Innovative Research in Computer and Communication Engineering

(An ISO 3297: 2007 Certified Organization)

Vol. 2, Issue 1, January 2014

Biological Early Detection of Nasal Dermoid Cyst Using CT/ MRI Scan - A Review

Neeraj Singla¹, Sugandha Sharma²

M.Tech Student, Dept. of CSE, CGC, Gharuan, Punjab, India¹

Assistant Professor, Dept. of CSE, CGC, Gharuan, Punjab, India²

ABSTRACT- Dermoid cyst occurs in brain, nasal, ovarian under which the nasal dermoid cyst surgery is very complicated when it occurs under which dermoid cyst early detection is possible by CT or MRI scan during pregnancy of lady so it will not occur and no need of surgery. Dermoid cysts are closed sacs that form within the body. A cyst may contain fluid, pus, some other tissue from the body, or foreign matter. Dermoid cysts form in or on the skin, usually on the face near the eyebrow, on the scalp, or on the chest over the collarbone. Rarely, a dermoid cyst near the surface of the body extends below the skin and connects to deeper structures. Very rarely, dermoid cysts develop in other areas of the body instead of the skin. Dermoid cysts are common in children. Most of the time they are painless and benign, which means they don't threaten your child's health. But they may become infected. Surgeons remove dermoid cysts to prevent infection.

Keywords: Dermoid Cyst, Radiological Imaging, Endonasal Surgery, Dermoid Sinus Cyst

I. INTRODUCTION

Dermoid Cyst: Dermoid cysts grow slowly and are not tender unless ruptured. They usually occur on the face, inside the skull, on the lower back and in the ovaries. Superficial dermoid cysts (ones near the surface of the skin) on the face can usually be removed without complications. Removal of other, rarer dermoid cysts requires special techniques and training.

These rarer dermoid cysts occur in four major areas:

- **DERMOID CYSTS IN THE BRAIN:** Dermoid cysts occur very rarely here. A neurosurgeon may need to remove them if they cause problems.
- **DERMOID CYSTS IN THE NASAL SINUSES:** These are also very rare. Only a handful of cases involving dermoid cysts located here are reported each year. Removal of these cysts is extremely complicated.
- **OVARIAN DERMOID CYSTS:** These growths can develop in a woman during her reproductive years. They can cause torsion (twisting), infection, rupture and cancer of the ovary. These dermoid cysts can be removed with either conventional surgery or laparoscopy (surgery that uses small incisions and specially designed instruments to enter the abdomen or pelvis).
- **DERMOID CYSTS OF THE SPINAL CORD:** A sinus tract, which is a narrow connection from a deep pit in the skin, usually connects these very rare cysts to the skin surface. This type of dermoid cyst can become infected. Removal is often incomplete, but the outcome is usually excellent.

Symptoms: The symptoms of epidermoid and dermoid tumors vary depending on their location. Cysts in the scalp are usually painless, moveable, rubbery masses that may slowly increase in size over time. The skin over the cyst is usually normal. Cysts in the bone may feel somewhat firmer and are usually less mobile. Although they usually only cause cosmetic problems, cysts in the skull may penetrate into the brain.

Diagnosis: Most scalp lesions can be accurately diagnosed by physical exam and x-rays or other imaging may not be needed. Lesions that appear to involve the skull usually require skull x-rays or less commonly, a CT or MRI scan to make sure that there is no penetration into the brain.

Treatment: Because of the potential to slowly enlarge and possibly penetrate through the skull, surgical removal is usually recommended. Most simple cysts can easily be removed with a short surgical procedure lasting less than an hour. Most children can go home the same day of surgery. Most children can resume regular activity, including bathing, in 2 to 3 days after surgery.

International Journal of Innovative Research in Computer and Communication Engineering

(An ISO 3297: 2007 Certified Organization)

Vol. 2, Issue 1, January 2014

II. COMPARATIVE STUDY

Cysts located in the brain are not truly “brain tumors” because they do not arise from the brain tissue itself. Although they tend to be (benign noncancerous), they are sometimes found in parts of the brain that control vital functions. There are four main types of cysts found in the brain:

- **Arachnoid Cyst** (also called Leptomeningeal Cyst): An enlarged, fluid-filled area of the subarachnoid space that occurs in both adults and children.
- **Colloid Cyst**: Although scientists are not sure of the definitive cause of colloid cysts, most agree that these cysts begin during embryonic development of the central nervous system. Malignant forms are unknown.
- **Dermoid Cyst**: These cysts most likely form during the early weeks of fetal development even though symptoms may not be noticed until years later. They are usually benign.
- **Epidermoid Cyst** (also called Epidermoid Tumor): Often referred to as epidermoid tumors. Likely form during the early weeks of fetal development even though the symptoms may not be noticed until decades later.

A. Location

Cysts can appear in a variety of locations within the brain.

- **Arachnoid Cysts** appear in the subarachnoid space (between the arachnoid and pia mater layers of the meninges).
- **Colloid Cysts** are typically attached to the roof of the third ventricle and the choroid plexus.
- **Dermoid Cysts**, though rarely found in the brain, are usually located at the lower back portion of the brain (the posterior fossa) in older adults and in the lower end of the spine in older children and young adults.
- **Epidermoid Cysts** tend to be located in the area where the top part of the brain meets the brain stem.

SIDE VIEW OF THE BRAIN

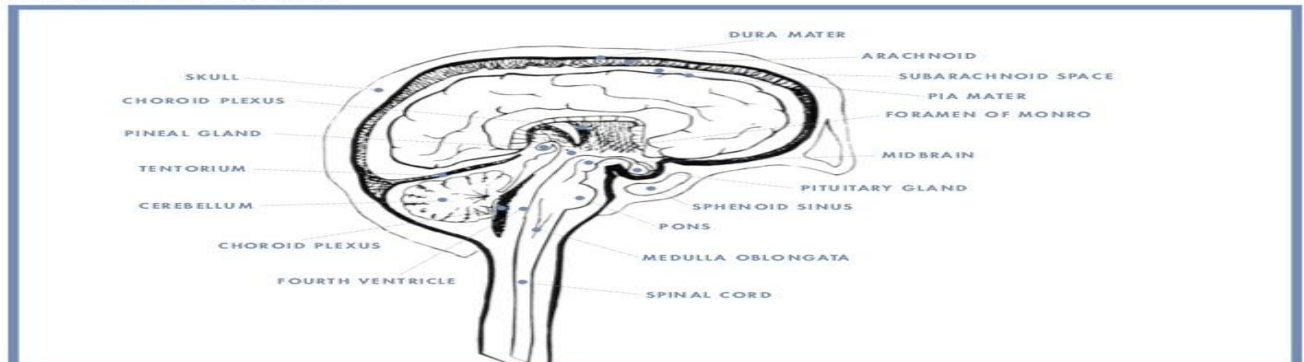


FIGURE -1[3]

B. Description

Just like a cyst anywhere else in your body, a cyst in the brain is a tumor-like sphere filled with fluid—much like a balloon filled with water. They may contain fluid, blood, tissue, or tumor cells.

- **Arachnoid Cysts** are enlarged, fluid-filled areas between layers of the covering of the brain.
- **Colloid Cysts** tend to contain a thick, gel-like substance called colloid.
- **Dermoid** and **Epidermoid Cysts** are tumor-like spheres.

Symptoms

Symptoms depend on the size and location of the cyst.

C. Incidence

- **Arachnoid Cysts** can be found in both adults and children.
- **Colloid Cysts** almost always occur in adults.
- **Dermoid Cysts** in the brain tend to occur in children under 10 years old.
- **Epidermoid Cysts** are most commonly found in middle-aged adults.

Cause

International Journal of Innovative Research in Computer and Communication Engineering

(An ISO 3297: 2007 Certified Organization)

Vol. 2, Issue 1, January 2014

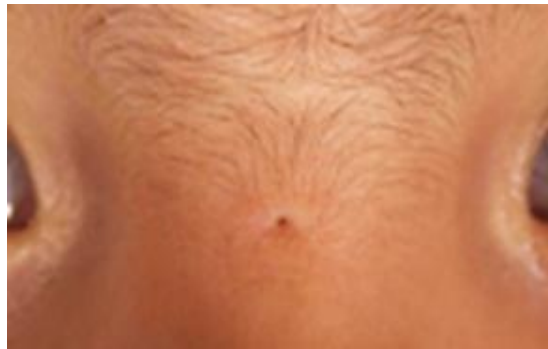The exact cause of cysts is unknown, but it is suspected that certain types form in the early weeks of fetal growth. Nothing specific can be done to prevent the development of cysts.

D. Treatment

The type, size, and location of the cyst determine how it will be addressed. Treatment methods for the various types of cysts are briefly explained below:

- **Arachnoid Cyst:** Treatment may be “watchful waiting,” or the cyst may require surgery.
- **Colloid Cyst:** Surgery is typically recommended. However, removal can be challenging because of its location.
- **Dermoid and Epidermoid Cysts:** Surgery is typically recommended. If complete removal is not possible, the remaining portion of the cyst may regrow. Fortunately, this growth may be very slow and it could be years before symptoms return.

Figure 2 : Dermoid cyst presenting as midline nasal mass



The nose is formed from the frontonasal process and two nasal placodes which develop dorsal to the *stomodaeum* (primitive mouth) during the fourth week of embryological life. The nasal placodes consist of medial and lateral processes and become more prominent. The medial processes approach one another and eventually fuse in the midline. The lateral processes become less prominent as the maxillary process fuses with them. A deep groove in this region, called the nasal-maxillary groove becomes the nasolacrimal duct. As the external nose develops, other neural crest cells migrate through the frontonasal process to form the posterior septum, ethmoid bone, and sphenoid. The nasal septum develops around week five from the frontonasal process, growing in an anterior-posterior direction. During formation of the skull base and nose, mesenchymal structures are formed from several centers that eventually fuse and begin to ossify. Before they fuse there are recognised spaces between them that are important in the development of congenital midline nasal masses. These include the fonticulus nasofrontalis, the prenasal space, and the foramen caecum (Figures 3a-c). The *fonticulus frontalis* is the space between the frontal and nasal bones. The prenasal space is located between the nasal bones and the nasal capsule (precursor of nasal septum and nasal cartilages). During foetal development these spaces are close by fusing and ossifying. Abnormal development of these structures is thought to be involved in the formation of nasal dermoids. A widely accepted theory of dermoid sinus cyst development is the prenasal space theory[7]

E. Pre-operative evaluation

Clinical evaluation

Encephalocoeles are pulsatile, compressible masses that expand on crying and on bilateral compression of the internal jugular veins (Furstenberg test); neither gliomas nor dermoids expand with crying or the Furstenberg test. However a negative Furstenberg test does not exclude intra-cranial extension; hence imaging is essential.

Radiological Imaging

If a dermoid is suspected, imaging is mandatory to determine the extent of the cyst or tract, to exclude an intracranial connection and to plan surgery. A CT scan delineates the bony anatomy and may indicate an intracranial connection (Figure 4).

International Journal of Innovative Research in Computer and Communication Engineering

(An ISO 3297: 2007 Certified Organization)

Vol. 2, Issue 1, January 2014

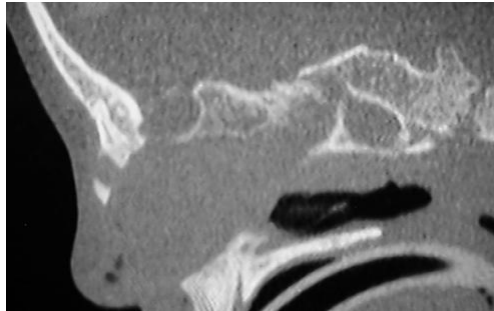


Figure 4: CT scan of nasal dermoid cyst

However, in order to exclude this, MRI scanning is required and is becoming the imaging method of choice, as both false-positives and false-negatives for intracranial involvement are found with CT. It is prudent in many cases (especially when a child requires general anaesthesia or sedation for imaging) to either obtain both images at a single sitting or to proceed directly to MRI scan (*Figure 5*).

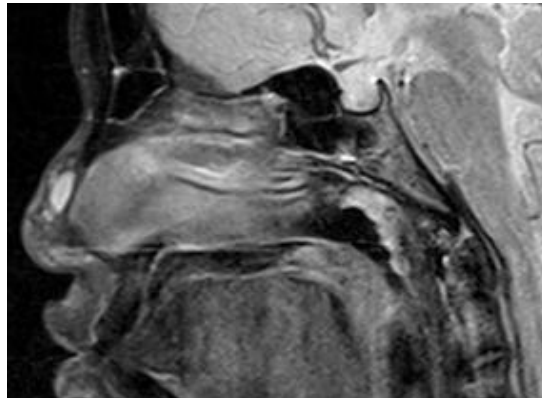


Figure 5: MRI scan of nasal dermoid cyst

II. CASE REPORT-SURGERY OF CHILD

Early surgical intervention is recommended to avoid further distortion of the nose or bony atrophy caused by growth of the mass or recurrent infection. [5] Biopsy is contraindicated due to risk of CSF leakage in cases with intracranial connections. The surgical objective is complete surgical excision at the first operation. Two factors determine the surgical approach

Several surgical approaches have been described; occasionally more than one incision is required especially in the presence of a nasal pit or skin breakdown

- A. Transverse rhinotomy Septorhinoplasty approach Vertical rhinotomy**
- B. Horizontal nasofrontal incision with eyebrow extensions**
- C. Endoscopic approaches**

A. Transverse rhinotomy: This can be used for small to moderate-sized lesions without intracranial extension. The sinus punctum is excised within a transversely oriented ellipse of skin and the tract is cannulated with a lacrimal probe and dissected. Medial or lateral osteotomies may be performed if necessary. If placed in a natural nasal skin crease it

International Journal of Innovative Research in Computer and Communication Engineering

(An ISO 3297: 2007 Certified Organization)

Vol. 2, Issue 1, January 2014

leaves a very favourable scar.

B. Open septorhinoplasty approach: This provides wide exposure, but with a concealed, aesthetically pleasing scar, for larger lesions and for patients with damaged bone and cartilage from prior surgery or recurrent infection or with intracranial extension. A separate excision of a sinus opening may be required; with intracranial extension a combined intracranial approach may be required.

C. Endoscopic approach: An endonasal endoscopic approach is recommended when a dermoid is located within the nasal cavity with little or no cutaneous involvement. It can be combined with a small external midline excision of the cutaneous punctum.[6] Although there are reports of adequate visualisation of the skull base through intercartilagenous incisions to allow passage of an endoscope and instruments, intracranial extension is a relative contraindication to endoscopic approach.

IV. FLOWCHART

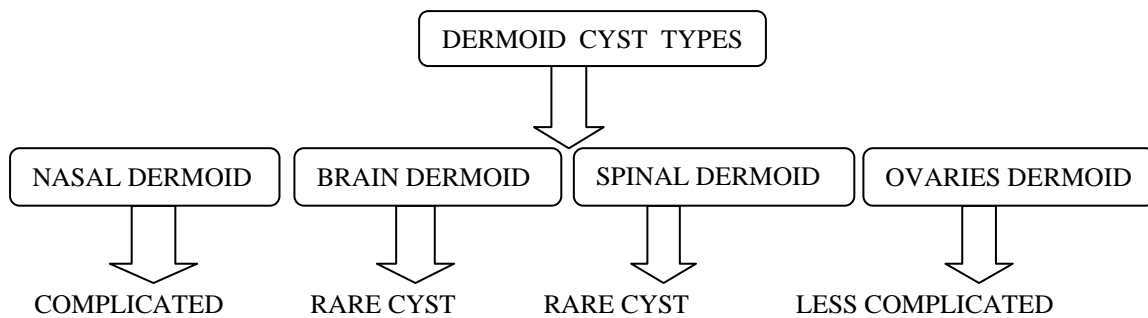
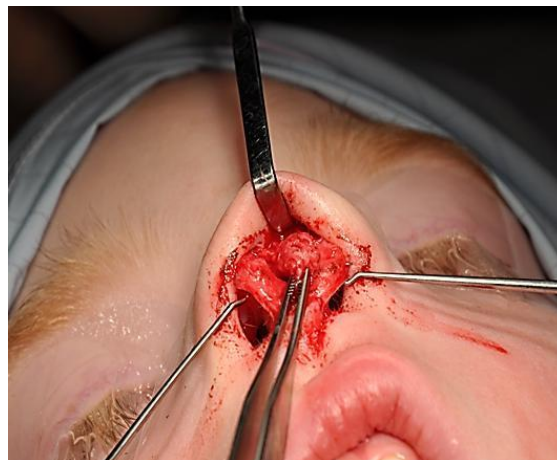
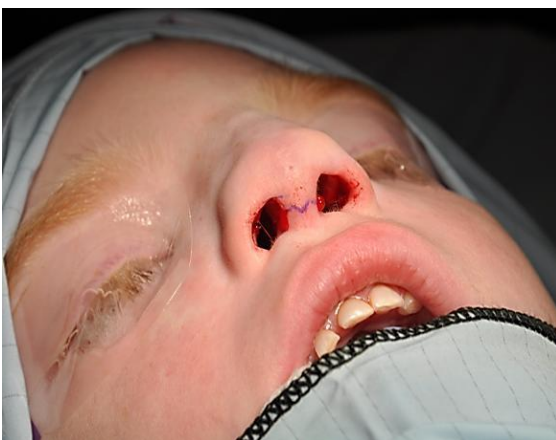

FIGURE -6- TYPES OF DERMOID CYST

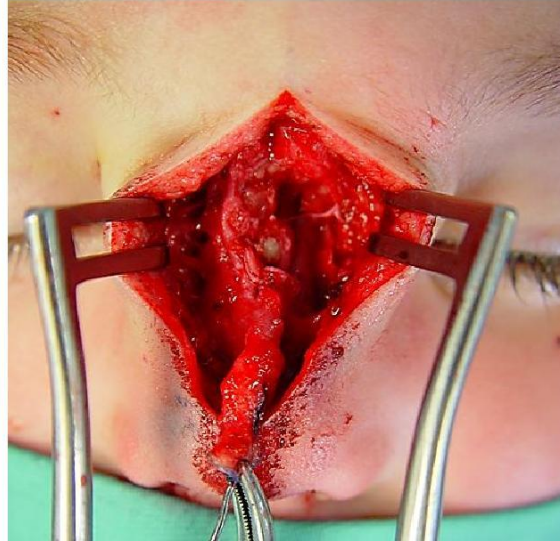
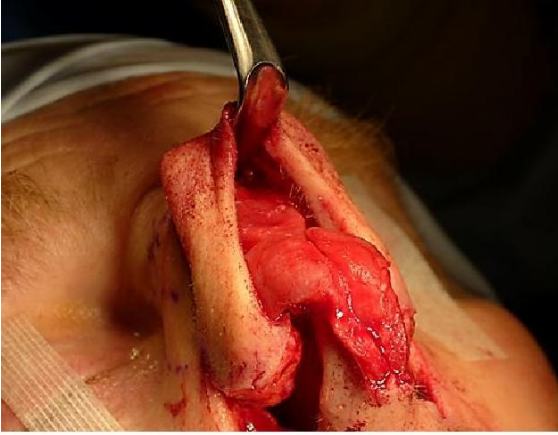
V. NASAL DERMOID SURGERY IS VERY COMPLICATED SO ITS EARLY DETECTION IS NECESSARY



International Journal of Innovative Research in Computer and Communication Engineering

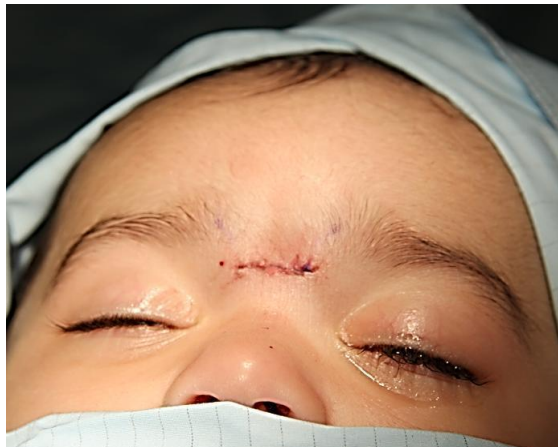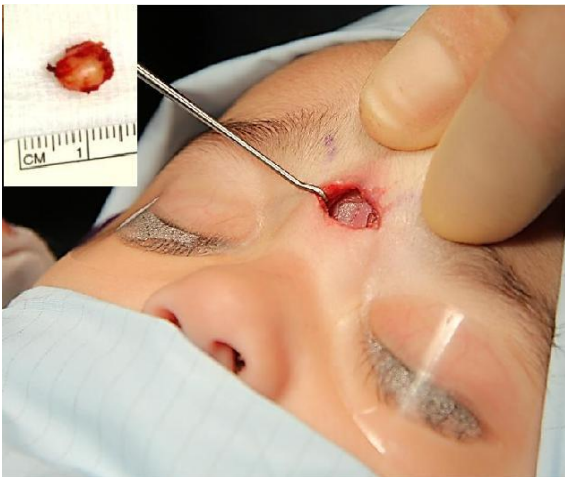
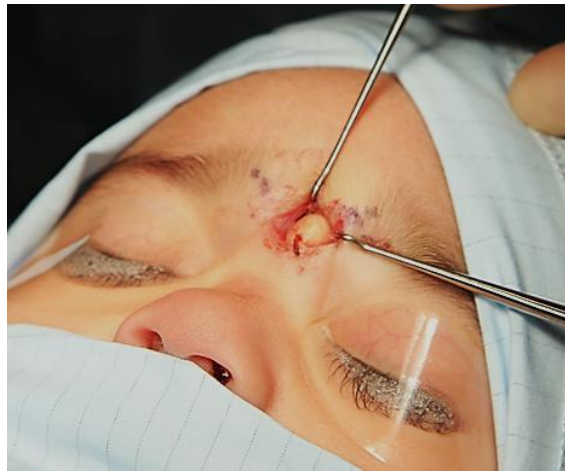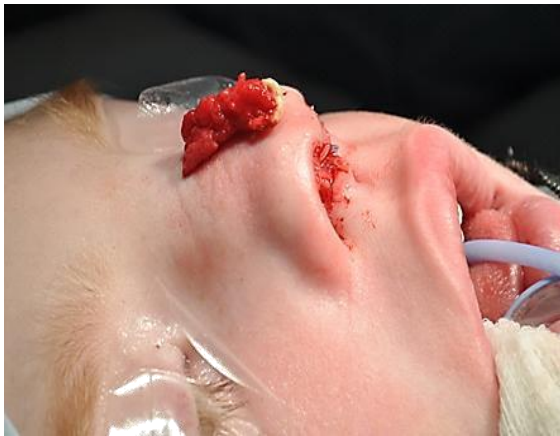(An ISO 3297: 2007 Certified Organization)

Vol. 2, Issue 1, January 2014



FIGURE—7

SURGERY
OF NASAL
DERMOID





International Journal of Innovative Research in Computer and Communication Engineering

(An ISO 3297: 2007 Certified Organization)

Vol. 2, Issue 1, January 2014

V.CONCLUSION

The dermoid sinus with or without cyst is an extensive lesion extending into the nasal cartilage and bone, usually passing deeply at the osteocartilaginous junction on the dorsum of the nose. The simplest cleft malformation in the frontobasal region is the dermal sinus which may be accompanied by dermoid cyst. This group includes a large proportion of the congenital nasal fistulas and dermoid cysts of the nose and frontal area, which are infrequently seen by the ENT surgeon. These fistulae may extend from the skin to the frontal bone leading to pressure atrophy and narrowing of the frontal sinus, if it is developed. They may extend through the skull base to the cranial cavity ending as an extradural cyst. Complete excision of dermoid cyst is treatment of choice. Surgical approaches for the removal of nasal dermoid depend upon extension of lesion. Different approaches have been advocated for removal of nasal dermoid which ranges from external approaches, such as midline vertical incision, transverse incision, lateral rhinotomy, external rhinotomy, inverted – U incision, degloving procedure and craniotomy for intracranial extension of nasal dermoid. Dermoid cyst is rare and often presents from birth appearing on the nose as a midline mass anywhere from the glabella to the columella. They rarely exceed 4 cm in size and possibly originate from inclusion of epidermal tissues in aberrant sites during embryonic development. Nasal dermoid cyst surgery is very complicated so its early detection is necessary.

REFERENCES

1. Rohrich RJ, Lwe JB, Schwart ., "The role of open rhinoplasty in management of nasal dermoid cysts", Pp223-254,2010.
2. Kelly JH, Strome M, Hall B." Surgical update on nasal dermoid. Arch Otolaryngology" pp:239-42., 2009
3. Hughes, et al." The management of the congenital midline mass-a review. Otolaryngology-Head and Neck Surgery" pp:222-23,2010.
4. Jaffe BF,," Classification and management of anomalies of the nose. Otolaryngologic Clinic of North America "pp:989-1004,2009.
5. Wardinsky, et al. "Nasal dermoid sinus cysts: Association with intracranial extension and multiple malformations." pp:87-95,2008..
6. Reza Rahbar, et al." The presentation and management of nasal dermoid. Arch Otolaryngology Head Neck Surg " Vol 129.,2011.
7. Pratt LW ". Midline cy-sts of the nasal dorsum: Embryologic origin and treatment. Laryngoscope"pp968-80.,2011.
8. Michelle Wyatt." Nasal obstruction in children. Scott Brown's Otolaryngology " 1073-74,2011..

BIOGRAPHY



ER. NEERAJ SINGLA, pursuing M.Tech -CSE from CGC, Gharuan and done B.Tech. degree from Punjab technical university. He is author of one international journals.



ER. SUGANDHA SHARMA is working as Assistant professor in CGC Gharuan in CSE department .. She completed her M.E in Computer Science and Engineering from University Institute of Engineering and Technology, Panjab University in 2010. She is Author of EIGHT International Journals. Fields of Specialization is Image Processing.