

## Evaluation of 115 Radicular Cysts: Histologic and Etiopathogenic Aspects for Clinicians.

Rajesh B Dhirawani<sup>1</sup>, Anand S Tegginamani<sup>2\*</sup>, and Wanjari Ghate Sonalika<sup>2</sup>.

<sup>1</sup>Department of Oral and Maxillofacial Surgery, Hitkarini Dental College & Hospital, Jabalpur, Madhya Pradesh, India.

<sup>2</sup>Department of Oral Pathology, Hitkarini Dental College & Hospital, Jabalpur, Madhya Pradesh, India.

### Research Article

Received: 15/02/2014

Revised: 14/03/2014

Accepted: 19/03/2014

#### \*For Correspondence

Department of Oral Pathology,  
Hitkarni Dental College &  
Hospital, Jabalpur,  
Madhya Pradesh, India.  
Mobile: +91 9845776409

**Keywords:** Chronic periapical  
periodontitis, Histopathology,  
Periapical lesion, Radicular Cyst

#### ABSTRACT

Radicular cysts (RCs) show distinct histopathological findings may be lined wholly or in part by non-stratified squamous epithelium, the scar fibrous connective tissue, few unexpected neoplasms have been reported and this an important insight into the knowledge of the histological variations of RCs. A total of 115 cases of RCs from the archives of Department of Oral Pathology evaluated for different varieties of epithelium among them 20% were non-stratified squamous epithelium, 27.82% with arcading pattern 7.82% cysts with sheets of epithelial cells with cleft formation 44.34% cysts without epithelial lining. The presence of only inflammatory connective tissue, which had modest to moderate intensity of the inflammatory infiltrate, 4.35% foamy macrophages/hyaline bodies and 6.96% cholesterol crystals. Most clinicians discard periapical tissue after surgical procedure rather than submitting those for histopathologic evaluation, and then losing potentially valuable illuminating information. The apical soft tissue lesion should be evaluated histopathologically, not to distinguish cyst versus granuloma, but to rule out unexpected neoplasms or more aggressive cysts.

#### INTRODUCTION

The microbiological factors and the host defense mechanism interact, destroying are large amount of periapical tissue, giving rise to the dissimilar types of periapical lesion. [1,2]

Radicular cysts are the most common inflammatory cysts and arise from the epithelial residues in the periodontal ligament as a result of periapical periodontitis following the death and necrosis of the pulp. Cysts arising in this fashion are found most usually at the apices of the involved teeth, but may also be set up on the lateral aspects of the foundations in relation to lateral accessory root canals. [3]

Most RCs develop slowly and do not grow very large in closed spaces. Patients do not feel pain unless acute inflammatory exacerbation is present. Large cysts may reason to mobility and not react to electrical pulp test in affected tooth. [4]

Radicular cysts show distinct histopathological findings may be lined wholly or in part by non stratified squamous epithelium, scar fibrous connective tissue few unexpected neoplasms have been reported and this an important insight into the cognition of the histological variations of RCs. Regrettably, most clinicians discard periapical tissue after surgical procedure rather than expressing them for histopathologic evaluation, and then losing a potentially valuable information source.

Therefore, the purpose of the present work was to describe the histopathological characteristics and possible variations of RCs and too brief review and update the etiopathogenic and histological aspects for clinicians

#### MATERIALS AND METHODS

115 cases diagnosed as RCs were included in the survey sample. The formalin-fixed, paraffin-embedded tissue was cut into 4- $\mu$ m thick sections for analysis. After staining with hematoxylin-eosin the tissues were

evaluated for epithelium [atrophic epithelium or hyperplastic epithelium], mucosal cells, and odontogenic epithelial remnants, eosinophilic bodies of Rushton, foamy macrophages, cholesterol crystals, and hyaline bodies.

### RESULTS

115 cases with 20% quiescent epithelium [Fig.1], 27.82% with arcading pattern [Fig.2] 7.82% cysts with sheets of epithelial cells with cleft formation [Fig.3] 44.34% cysts without epithelial lining. The presence of only inflammatory connective tissue, which caused modest to moderate intensity of the inflammatory infiltrate, 4.35% foamy macrophages/hyaline bodies and Cholesterol crystals 6.96% [Fig.4], Rushton bodies were not present in any of this cystic epithelium nor were any other malignancy or other pathologies found in this field.

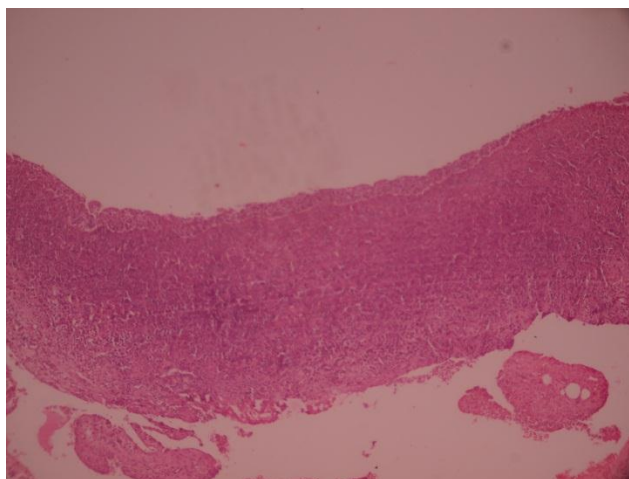


Figure 1

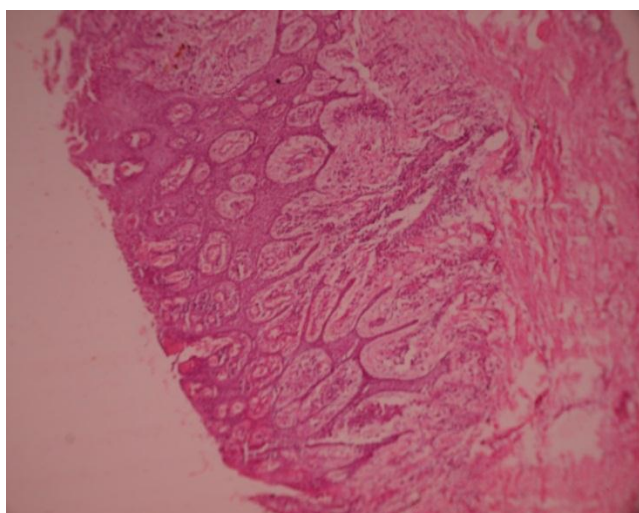


Figure 2

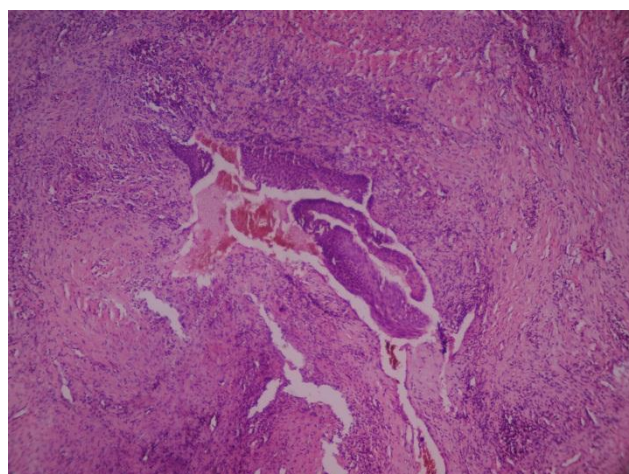


Figure 3

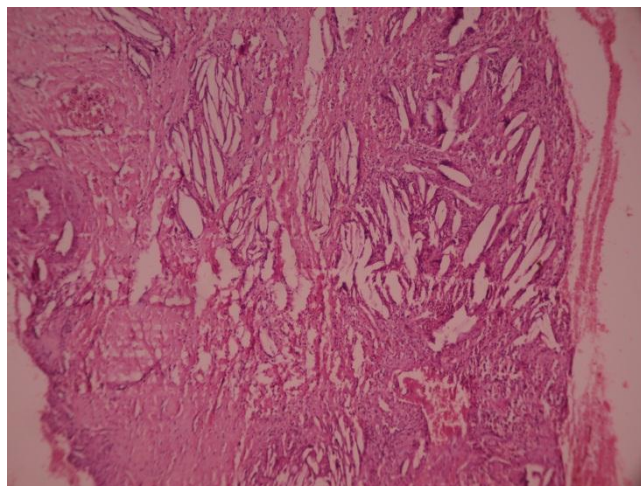


Figure 4

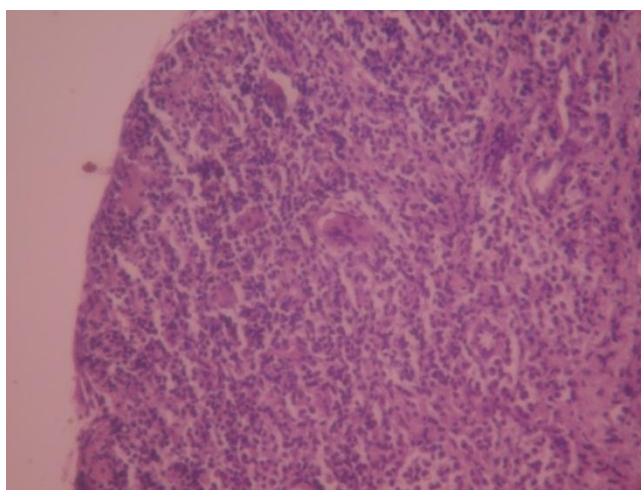


Figure 5

## DISCUSSION

RCs accounts for 6% to 57.69% of all periapical lesions [5] Most radicular cysts develop slowly and do not get very large pits. Patients do not feel pain unless acute inflammatory exacerbation is present. Large cysts may reason to mobility and not react to electrical pulp test in affected tooth. [6]

The etiopathogeny of cysts is particularly controversial; their constitution has been explained by various theories, such as epithelial colonization, epithelial cavitations, or the formation of micro abscesses.[7]

The pathogenesis involves the activation of epithelial cell rests of Malassez after physical, chemical or bacterial injury. Three forms of cystic formation have been described: initiation, cyst formation and cyst enlargement, only in the event of chronic irritation, direct microorganism invasion leads to pulp necrosis. Actinomyces are the most commonly occurring organisms in an infected radicular cyst. [8-10]

The radicular cyst is the model pathogenesis of an inflammation-stimulated cyst and has been extensively considered. The origin of the cyst epithelium lies with rests of Malassez, which are epithelial remnants of Hertwig epithelial root sheath that lie dormant within the periodontal ligament. The products of pulpal infection and necrosis spill out into the periapical tissues, inciting an inflammatory reaction. The inflammatory cells secrete a host of lymphokines to neutralize, immobilize, and degrade bacteria. They also cause bone resorption through the elaboration of interleukin-1 and osteoclast-activating factors. These same cells are intended to elaborate many other elements that either immediately or indirectly acts as epithelial growth factors, stimulating the proliferation of the rests of Malassez in the periapical granuloma. As the epithelial cell mass enlarges, the central cells become distant from their blood supply and break down, thereby forming a cyst. The cyst continues to blow up by epithelial proliferation in the lining and by hydrostatic pressure generated in the cyst lumen from the hyperosmolarity created

by cellular breakdown and sloughing of cells into the lumen. Thus, the osmotic gradient favors transudation of fluid into the lumen, which maintains its hydrostatic pressure and causes further resorption of the surrounding bone. [3,11,12]

Almost all radicular cysts are lined wholly or in part by stratified squamous epithelial tissue. These liners may be discontinuous in part and range in thickness from 1 to 50 cell layers. The majority are 6–20 cell layers thick, in early cysts, the epithelial lining may be proliferative and show arcading with an intense associated inflammatory process the inflammatory cell infiltrate in the proliferating epithelial linings consists predominantly of polymorphonuclear leucocytes whereas the adjacent fibrous capsule is infiltrated mainly by chronic inflammatory cells. But as the cyst enlarges the lining becomes quiescent and fairly regular with a certain degree of differentiation to resemble a simple stratified squamous epithelium.<sup>[3]</sup>

Hyaline bodies were of haematogenous origin, and were derived from thrombi in venules of the connective tissue that had become varicose and strangled by epithelial cuffs which encircled them. Some puzzling features about their distribution if they are of vascular and haematogenous origin, there are very few reports of hyaline bodies in cysts other than radicular cysts.

Although the origin of hyaline bodies remains obscure, it is generally at once thought that they represent a secretory product of odontogenic epithelium. [13]

Suggested that this irritated the epithelial cells to produce a fine-grained matrix which enclosed the coarse-grained foreign material and then underwent different degrees of 'homogenisation'. This they called the hyaline body type II. The type I hyaline body, they hinted, has no central granular component. Hyaline body types I and II always consisted of a fine-grained substance which underwent 'homogenization' and consistently contained calcium and phosphate. <sup>[3]</sup>

Deposits of cholesterol crystals are found in many radicular cysts, but by no means in all main sources of cholesterol was from disintegrating red blood cells in a form that readily crystallises in the tissues, Once the cholesterol crystals have been deposited in the fibrous capsules of the cysts, they behave as foreign bodies and excite a foreign body, giant cell reaction, the cholesterol crystals are dissolved out and clefts are seen surrounded by dense aggregations of multinucleate giant cells.<sup>[6]</sup>

The incidence of cholesterol crystals in periapical lesions varies between 18% and 44% of all lesions.<sup>[14]</sup>

A few well-documented instances have been reported which indicate that squamous carcinoma may occasionally arise from the epithelial lining of radicular and other odontogenic cysts keratin metaplasia in long-standing radicular and dentigerous cysts may precede malignant change and models of epithelial dysplasia are at times seen in jaw cysts without any evidence of carcinomatous transformation. There is no evidence, yet, that cyst epithelium is at particular danger and there is thus no justification for regarding cysts as precancerous lesions. [3,15]

Squamous odontogenic tumor-like proliferation in a radicular cyst have also been described. <sup>[16]</sup>

Both radicular cyst and dentigerous cyst were synchronous seen in the same patient. <sup>[17]</sup>

Radicular cysts can heal spontaneously after root canal treatment or extraction. Nevertheless, some authors propose that suspected radicular cysts must be totally enucleated surgically to get rid of all epithelial remnants. [18]

Extraction or endodontic treatment of the affected tooth is required when clinical and radiographic characteristics indicate a periapical inflammatory lesion. The normal treatments for radicular cysts include total enucleation in the case of small lesions, marsupialisation for decompression of larger cysts, or a compounding of the two techniques. Inflammatory cysts do not recur after adequate treatment. <sup>[19]</sup>

## CONCLUSION

The apical soft tissue lesion should be evaluated histopathologically, not to distinguish cyst versus granuloma, but to rule out unexpected neoplasms or more aggressive cysts, A few well-documented instances have been reported which indicate that squamous carcinoma may occasionally arise from the epithelial lining of radicular and other odontogenic cysts. [15,20] however histologic study is required for all periodical tissues after operation. Regrettably, most clinicians discard periapical tissue after surgical procedure rather than stating them for histopathologic evaluation, so missing a potentially valuable informative data.

## REFERENCES

1. Liapatas S, Nakou M, Rontogianni D. Inflammatory infiltrate of chronic periradicular lesions: an immunohistochemical study. *Int Endod J.* 2003;36(7):464-71.
2. Hama S, Takeichi O, Hayashi M, Komiyama K, Ito K. Co-production of vascular endothelial cadherin and inducible nitric oxide synthase by endothelial cells in periapical granuloma. *Int Endod J.* 2006; 39(3):179-84.
3. Shear M, Speight P. *Cyst of the oral and Maxillofacial Regions in dentigerous cyst* Fourth ed Oxford, England, UK: Blackwell Munkgaard Publication; 2007. p. 123-142.
4. Delbem ACB, Cunha RF, Vieira AEM, Pugliesi DMC. Conservative treatment of a radicular cyst in a 5-year-old child: a case report. *Int J Paediatr Dent.* 2003; 13: 447-450.
5. Santos L.C.S. et al. Histopathological Study of Radicular Cysts Diagnosed in a Brazilian Population *Braz Dent J.* 2011; 22(6): 449-454.
6. Delbem ACB, Cunha RF, Vieira AEM, Pugliesi DMC. Conservative treatment of a radicular cyst in a 5-year-old child: a case report. *Int J Paediatr Dent.* 2003; 13: 447-450.
7. Gay C. Lesionesperiapicales. In: Gay C, Berini L eds. *Cirugiabucal.* Madrid: EdicionesErgon; 1999.p.749-80.
8. Mosqueda-Taylor A, Irigoyen-Camacho ME, Diaz-Franco MA, Torres-Tejero MA. Odontogenic cysts. Analysis of 856 cases. *Med Oral.* 2002; 7:89-96.
9. Nair PN, Henry S, Cano V, Vera J: Microbial status of apical root canal system of human mandibular first molars with primary apical periodontitis after "one-visit" endodontic treatment. *Oral Surg Oral Med Oral Pathol Oral Radiol Endo.* 2005; 99:231-252.
10. Gopikrishna V, Parameswaran A, Kandaswamy D: Criteria for management of calcific metamorphosis: review with a case report. *Indian J Dent Res.* 2004; 15:54-57.
11. Meghji S, Qureshi W, Henderson B. and Harris M. The role of endotoxin and cytokines in the pathogenesis of odontogenic cysts. *Arch Oral Biol.* 1996; 41, 523-531.
12. Grupe H.E. Jnr., Ten Cate A.R. Zander H.A. A histochemical and radiobiological study of in vitro and in vivo human epithelial cell rest proliferation. *Arch Oral Biol.* 1967; 12, 1321-1329.
13. Jacob S. Rushton bodies or hyaline bodies in radicular cysts: A morphologic curiosity *Indian J PatholMicrobiol.* 2010;53(4):846-847.
14. Trott JR, Chebib F, Galindo Y. Factors related to cholesterol formation in cysts and granulomas. *J Can Dent Assoc.* 1973;39(8):550-5.
15. Neville B W. pulp and periapical disease. *Oral and Maxillofacial Pathology* 2nd Ed 2002 .p.120-121.
16. Sala-Pérez S, Marco-Molina V, Gay-Escoda C. Squamous odontogenic tumor-like proliferation in a radicular cyst: A case report. *J ClinExp Dent.* 2013;5(5):e298-301.
17. Aslan, Aras, Şimşek, Dayi large dentigerous and radicular cysts of the mandible *Atatürk ÜnivDişHekFakDerg.* 2006;16(1): 54-58.
18. Walton RE. The residual radicular cyst: does it exist? *Oral Surg Oral Med Oral Pathol Oral RadiolEndod.* 1996; 82 (5):471.
19. Penumatsa VN, Nallanchakrava S, Muppa R, DandempallyA, Panthula P Conservative Approach in the Management of Radicular Cyst in a Child: Case Report. *Case Rep Dent.* 2013; 1: 1-3.
20. Marx R E & Stern D. *Odontogenic& non Odontogenic Cysts in Oral and Maxillofacial Pathology: A Rationale for Diagnosis and Treatment.* 2012 2nd edition. p. 574.