

Research and Reviews: Journal of Medical and Health Sciences

Hormone Receptor Positivity Is Strong Prognostic Factor In Breast Carcinoma A Level IV Evidence

Anup Kumar*

Assistant Professor, Department of Radiotherapy, RIMS, Ranchi, India.

Short Communication

Received: 08/04/2013

Revised: 17/04/2013

Accepted: 25/04/2013

*For Correspondence

Assistant Professor, Department of
Radiotherapy, RIMS, Ranchi, India.

Key words: Metastatic Breast
Carcinoma (MBC)

ABSTRACT

A 60year old lady presented to Oncology OPD with complains of lump over left breast of 2 year duration, after metastatic workup, she was diagnosed as cancer of left breast with lung and bone mets, or metastatic breast carcinoma,(MBC) additional investigation done at this point was her ER/PR receptor status, she was found to be ER/PR receptor positive, later on she was planned for chemotherapy, then she was put on aromatase inhibitor till progression of disease. She showed remarkable response to the treatment and almost survived for about two and half year after the diagnosis of MBC.Review of literature has been done with respect to the management in post menopausal women who are positive to these receptors.

INTRODUCTION

Hormone receptor status is a strong prognostic factor . Most breast cancers are estrogen and/or progesterone receptor positive. In hormone receptor positive breast cancers estrogen,progesterone or both bind to the cancer cells in lock and key fashion and encourage the cells to proliferate.Hormone receptor positive breast cancers have a much better prognosis because they can be treated with antihormonal agents such as tamoxifen or newer aromatase inhibitors.

CASE REPORT

A 60 year old lady presented in oncology OPD with history of lump over left breast of 24 months duration in July 2010. On local examination it was found that her whole left breast was replaced by growth which was hard in consistency, fixed to the superficial skin and underlying muscle, multiple enlarged, hard, matted lymph nodes felt over left axilla, left supraclavicular lymph nodes were also palpable. Her metastatic work up was done with X-ray chest PA view, USG abdomen & pelvis and routine blood investigation . X-ray chest showed marked pleural effusion then CECT chest got done for detail study which showed massive pleural effusion on left side with collapse of underlying lung.(pic-1) Bone scan showed increased tracer uptake over T9 vertebra b/l lateral malleoli and left patella.(pic-2) True cut biopsy was taken from left breast mass for documentation regarding ER/PR status, which was found to be positive. A diagnosis of metastatic carcinoma of left breast with secondaries to lung was made. After explaining the pros and cons she was planned for chemotherapy with 5-FU, Doxorubicin and cyclophosphamide. She completed her 6 cycle of chemotherapy in March 2011, underwent palliative radiotherapy to T9 vertebra. She showed remarkable response to therapy. Her general condition improved and almost complete disappearance of pleural effusion, thereafter she was put on letrozole 2.5 mg along with oral bisphosphonates and calcium. She was doing well till March 2012 then she developed loss of weight, dyspnoea on moderate work and loss of performance status. She was asked to receive Fulvestrant, due to poor financial condition they were not able to afford it, subsequently she was planned for 3 cycles of chemotherapy with docetaxel. Patient showed symptomatic response then she was put on exemestane 25 mg OD, we lost this patient in the last week of December 2012. She lived for almost 2 and 1/2 years after the diagnosis of metastatic cancer of breast.

DISCUSSION

Breast cancer is the most common malignancy among women in the developed countries. Although impressive improvements have been made in the adjuvant treatment of early breast cancer, ~20% of patients initially diagnosed with regional stage disease will

develop metastatic breast cancer(MBC).The medical treatment of MBC offers a wide range of options including chemotherapy, endocrine treatment,therapy with antibodies directed against growth factors relevant to the disease, tyrosine kinase inhibitors (TKI) and supportive measures. The abundance of treatment option has contributed to an impressive amelioration of prognosis in a proportion of patients with MBC.

Treatment choices for MBC are guided by

- Hormone receptor [estrogen receptor (ER)and progesterone receptor(PgR)] status of the primary tumor or its metastases,
- HER-2/ *neu* status,
- The duration of the relapse-free interval since primary diagnosis and since completion of adjuvant therapy for breast cancer,
- The location and extent of metastases(visceral versus nonvisceral),
- Previous treatment (including its effects and tolerance),
- Patients symptoms,
- Patients preferences,
- Anticipated side-effects of treatment and
- The availability and access to the treatment. [4]

Cytotoxic chemotherapy remains the mainstay of treatment for women with metastatic breast cancer,irrespective of hormone receptor status,and is the back bone of many novel treatments incorporating biological therapy . Chemotherapy has substantial side effects,including fatigue,nausea,vomiting,myelosuppression,neuropathy,diarrhea,and alopecia. For this reason, chemotherapy treatment of women for advanced breast cancer involves tradeoffs between cancer palliation and toxicities of therapy. Chemotherapy is used in patients with hormone refractory or hormone-insensitive tumors [2].

Clinical trials have addressed a number of important treatment principles for use of chemotherapy in women with metastatic breast cancer. Tumor response to chemotherapy is a surrogate for longer cancer control and survival. First-line treatment is associated with higher response rate and longer tumor control than second-line,and so forth. There are relatively few studies of fourth or higher lines of chemotherapy,although patients often receives many lines of treatment. Trials have demonstrated palliative benefits of chemotherapy in patients with refractory tumors receiving third-line or subsequent chemotherapy treatment,but the magnitude of such gains must be realistically weighed against the side effects of treatment [2].

About 80% of breast cancers expresses either or both the estrogen receptor(ER) and the progesterone receptor (PgR). In patients with hormone receptor positive advanced breast cancer, endocrine therapy is a fundamental part of the therapeutic strategy.(1) Estrogen and progesterone receptor expression are the most important and useful predictive factors currently available.Patients with invasive breast cancer whose tumors are totally lacking in ER and PR do not derive benefit from hormonal treatment either in metastatic or adjuvant setting.Current assays for ER and PR are performed using IHC techniques which have the advantages of not being confounded by endogenous estrogens can be correlated with histological findings to eliminate the possibility that the assessment was done on non cancerous tissue ,can be done on paraffin embedded tissues and donot have tumor size as a limiting factor.Laboratories need to adhere to well described techniques to ensure accurate determination of ER and PR. A recent report from ASCO and the college of American pathology has highlighted the importance of high quality ER and PR testing as a centerpiece of breast cancer care [2].

Patients relapsing during or within 12 months after the end of adjuvant endocrine treatment are considered resistant to the specific endocrine drug and should be offered alternative therapies.

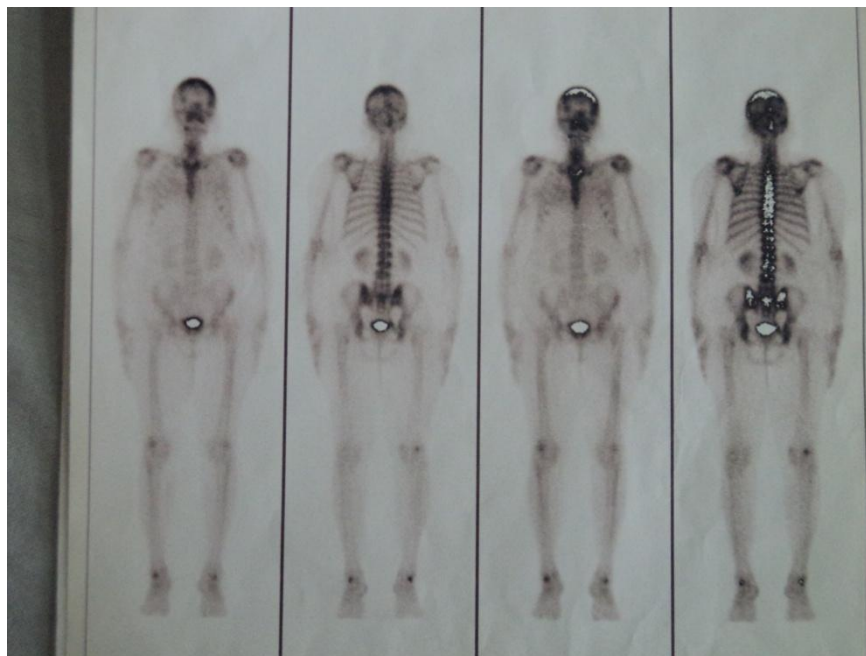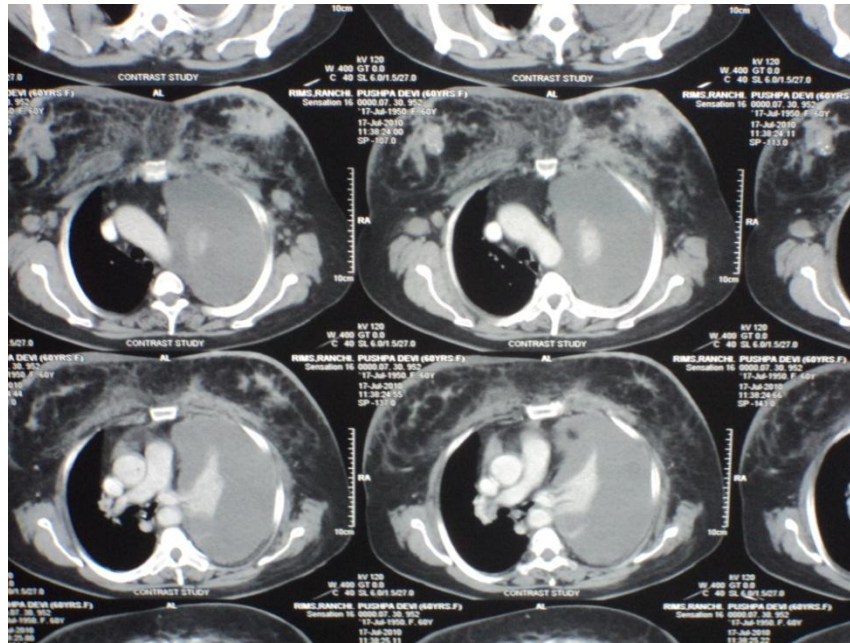
Briefly, the following recommendations have been reconfirmed for the endocrine treatment of postmenopausal patients with hormone receptor positive MBC:

- The use of a third-generation nonsteroidal (anastrozole and letrozole) or steroidal (exemestane) aromatase inhibitor was recommended as first line treatment with tamoxifen remaining to constitute a valuable option.
- Following tamoxifen failure, a third-generation aromatase inhibitor or the selective ER downregulator fulvestrant is recommended for second line treatment.
- Following failure of a third-generation nonsteroidal aromatase inhibitor, a steroidal aromatase inhibitor tamoxifen (or toremefin), fulvestrant, progestins, estrogens or androgens may be considered [4].

Treatment with aromatase inhibitors in combination with HER-2 targeting agents is a suitable option for patients with HER-2 positive/hormone receptor-positive tumors [1].

Second line treatment with exemestane along with the mTOR inhibitor everolimus has proven to be superior to the single agent exemestane , thus establishing a new benchmark in this disease setting [1]. In general up to 60 % of pts with hormone receptor positive

advanced breast cancer respond to hormonal therapy. Premenopausal patients can be treated with tamoxifen, ovarian ablation / suppression or the combined strategy, when used as first line therapy. Tamoxifen is associated with a response rate in the range of 50% and median time to progression of 12-18 months can be observed. In a meta analysis of four randomised clinical trials and a median follow up of 6.8 yrs, the combined strategy was superior in terms of response rate, time of progression and overall survival. Ovarian suppression/ablation is a therapeutic strategy to pts who progress on tamoxifen therapy. Although combination of ovarian suppression with aromatase inhibitors is sometimes prescribed no randomised clinical trial addressing this treatment combination has yet been presented and this strategy should be restricted to clinical trials [3].



CONCLUSION

In a country like India where cost of treatment and investigation is an issue, we can ask for at least ER/PR status as it is an established fact that there is improved survival with Aromatase inhibitors even in metastatic disease in postmenopausal women positive for these receptors.

REFERENCES

1. Filippo Montemurro, Valentina Rossi, Elena Geuna, Giorgio Valabrega, Rossella Martinello, Andrea Milani et al. Current status and future perspectives in the endocrine treatment of post menopausal, hormone receptor-positive metastatic breast cancer. *Expert Opin Pharmacother.* 2012; 13(15): 2143-2144
2. Vincent T Devita Jr, Theodore S Lawrence, Steven A Rosenberg. *Cancer Principles and practice of Oncology.* 9th edition. Philadelphia: Lipincott Williams & Wilkins;2011. Chapter-106, page no 1427, 1441.
3. Otto Metzger Filho, Evandro De Azambuja, Martine Piccart-Gebhart. Targeted therapies in breast cancer. In: Manfred Schwab, editor. *Encyclopedia of Breast Cancer.* Houten, The Netherlands: Springer 2010. 2nd edition Page no 683-85.
4. S Beslija, J Bonneterre, HJ Burstein, V Cocquyt, M Gnant, V Heinemann, et al. Third consensus on medical treatment of metastatic breast cancer. *Ann Oncol.* 2009;20:1771-1773.