

Research & Reviews: Journal of Medical and Health Sciences

Incidental Detection of Adrenal Myelolipoma: A Rare Case Report

Singh Harpal*, Kundal Ramesh, Pooja Garg and Ninder Kumar
Department of pathology, Govt. Medical College, Patiala, Punjab, India

Case report

Received date: 19/11/2015

Accepted date: 14/12/2015

Published date: 21/12/2015

*For Correspondence

Dr. Harpal Singh, Associate Prof. Pathology, GMC Patiala, # 835/13 Ghuman Nagar A, Sirhind Road Patiala- 147001, Punjab, India, Tel: 09417880849.

E-mail: drharpalseemar@gmail.com

Keywords: Myelolipoma, Right hypochondrium, Laparotomy, Microscopy, Liposarcoma.

INTRODUCTION

Adrenal myelolipoma is a rare, endocrinologically inactive neoplasm. It was initially described by Giercke in 1905, and 24 years later, Oberling coined the term 'myelolipoma'^[1]. Duckman and Freedman in 1957 presented the first symptomatic case treated surgically, and De Boils & De May reported the first case of radiologically diagnosed incidentaloma^[2]. In the past, these lesions used to be primarily detected at autopsy. Recently, with widespread use of noninvasive imaging modalities such as ultrasonography, computed tomography and magnetic resonance imaging, incidental detection is more common, affecting men and women equally^[3]. Accounting for 3–5% of all primary tumors of the adrenals, the true incidence of these tumors is not known, although it is thought to be 0.08%–0.4%, with increased incidence noted in the later decades of life^[4].

CASE REPORT

44 year male patient having only dull aching pain in right hypochondrium, no other clinical Dhistory given by patient. The patient was subjected to an USG of the abdomen which showed a well encapsulated, echogenic, right supra-renal mass of size 62 mm X 61 mm. The remainder of the USG was normal.

A CT scan of the abdomen revealed a well circumscribed, heterogeneous, non enhancing mass of size 50 x 67 x 55 mm in the right supra-renal region causing downward displacement of the right kidney (**Figure 1**) The lesion showed hypodense areas with CT attenuation values suggestive of fat. The function of both kidneys appeared normal. Patient underwent exploratory laparotomy and a surgical right adrenalectomy was performed and tissue sent for histopathological examination. Gross examination of the specimen revealed a large, rounded, and encapsulated mass with smooth external surface measuring 9 x 6 x 3 cm. Cut surface revealed a solid tumor with a variegated appearance of dark brown and yellowish area (**Figure 2**) Microscopy revealed a characteristic admixture of mature adipose tissue with hematopoietic elements, thus confirming the initial diagnosis of adrenal myelolipoma (**Figure 3a and 3b**).

DISCUSSION

Adrenal myelolipoma constitutes a rare tumor. They are composed of variable proportions of mature adipose tissue and active hematopoietic elements. They are also called "incidentalomas" since their diagnosis is based on autopsy or imaging modalities which are performed for reasons usually unrelated to adrenal diseases. Incidence ranges from 0.08% to 0.4%^[5]. However, their prevalence appears to be increasing up to 10%, due to the increased use of noninvasive and enhanced imaging techniques^[6].

Several theories have been proposed regarding the etiology of these tumours, the most accepted of which is that proposed

by Meaglia and Schmidt in 1992. They proposed that myelolipomas arise due to metaplasia of the reticulo-endothelial cells of blood capillaries in the adrenal gland in response to stimuli such as infection, stress or necrosis [7].

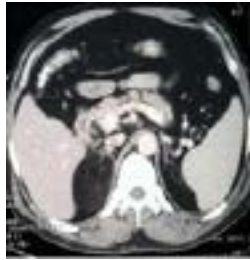

Figure 1. “Contrast-enhanced computed tomography (CECT) scan of abdomen revealed a well-defined, enhancing hypodense fat density lesion in the right suprarenal region suggesting the possibility of myelolipoma.”

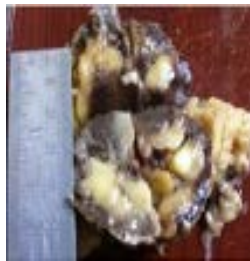

Figure 2. “Cut Surface of adrenal myelolipoma showing a variegated appearance of dark brown and yellowish areas.”

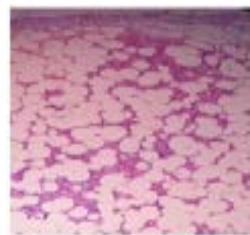


Figure 3a. Under 10x.

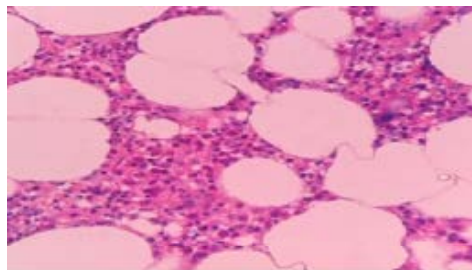


Figure 3 (b). “Microscopic appearance of adrenal myelolipoma. Typical histological features of myelolipoma comprising varying proportions of adipose tissue admixed with areas of hematopoietic tissue (H & E stain, Figure 3a under 10x and figure 3b under 40x.”

The conditions often associated with adrenal myelolipomas include Cushing's disease, obesity, hypertension, and diabetes which can be characterized as major adrenal stimuli [8]. Several case series have reported the predominance of the tumor in the right adrenal gland, which is yet to be explained [9]. The most well-recognized complication of adrenal myelolipoma is spontaneous retroperitoneal haemorrhage [7,10].

Ultrasonography, computed tomography, and MRI are all effective in diagnosing more than 90% of adrenal myelolipoma on the basis of identification of fat, with CT scan being the most sensitive [3,9]. Since these tumors are nonfunctional, endocrinological evaluations may not be useful, although there is a report of a secreting myelolipoma causing hypertension [4]. The differential diagnosis should include renal angiomyolipoma, retroperitoneal lipoma, and liposarcoma [11].

CONCLUSION

We conclude that adrenal myelolipomas are rare tumours, they can be misdiagnosed as angioliipoma if not considered. Most important clue for diagnosis is various imaging modality (USG and CT) as well as histopathological examination togetherly. Asymptomatic small tumors, smaller than 4 cm, may be monitored with watchful waiting. Symptomatic tumors greater than 4 cm should be extirpated because of the risk of spontaneous rupture with retroperitoneal bleeding. Bilateral adrenalectomy to big tumors implies medical replacement with hydrocortisone.

REFERENCES

1. Ersoy E, et al. Giant adrenal myelolipoma associated with small bowel leiomyosarcoma: a case report. *The Turkish Journal of Gastroenterology*. 2006;17:126–129.
2. Yolanda AV. Mielolipoma de la glandula suprarenal: Informe de un caso y revision de la literura. *Arch. Esp. Urol*. 2006;59:71-73.
3. Daneshmand S and Quek ML. Adrenal myelolipoma: diagnosis and management. *Journal of Urology*. 2006;3:71–74.
4. Brogna A, et al. Giant secreting adrenal myelolipoma in a man: a case report. *Journal of Medical Case Reports*. 2011;5:298.
5. Settakorn J, et al. Fine-needle aspiration cytology of adrenal myelolipoma: case report and review of the literature. *Diagnostic Cytopathology*. 1999;21:409–412.
6. Porcaro AB, et al. Incidentally discovered adrenal myelolipoma. Report on 3 operated patients and update of the literature. *Archivio Italiano di Urologia, Andrologia*. 2002;74:146–151.
7. Meaglia JP and Schmidt JD. Natural history of an adrenal myelolipoma. *Journal of urology*. 1992;147:1089-1090.
8. Tyritzis SI, et al. Giant adrenal myelolipoma, a rare urological issue with increasing incidence: a case report. *Cases Journal*. 2009;2:8863.
9. Kenney PJ, et al. Myelolipoma: CT and pathologic features. *Radiology*. 1998;208:87–95.
10. Lawler LP and Pickhardt PJ. Giant adrenal myelolipoma presenting with spontaneous hemorrhage: CT, MR and pathology correlation. *Ir Med J*. 2001;94:231.
11. Répássy DL, et al. Giant adrenal myelolipoma. *Pathology & Oncology Research*. 2001;7:72–73.